

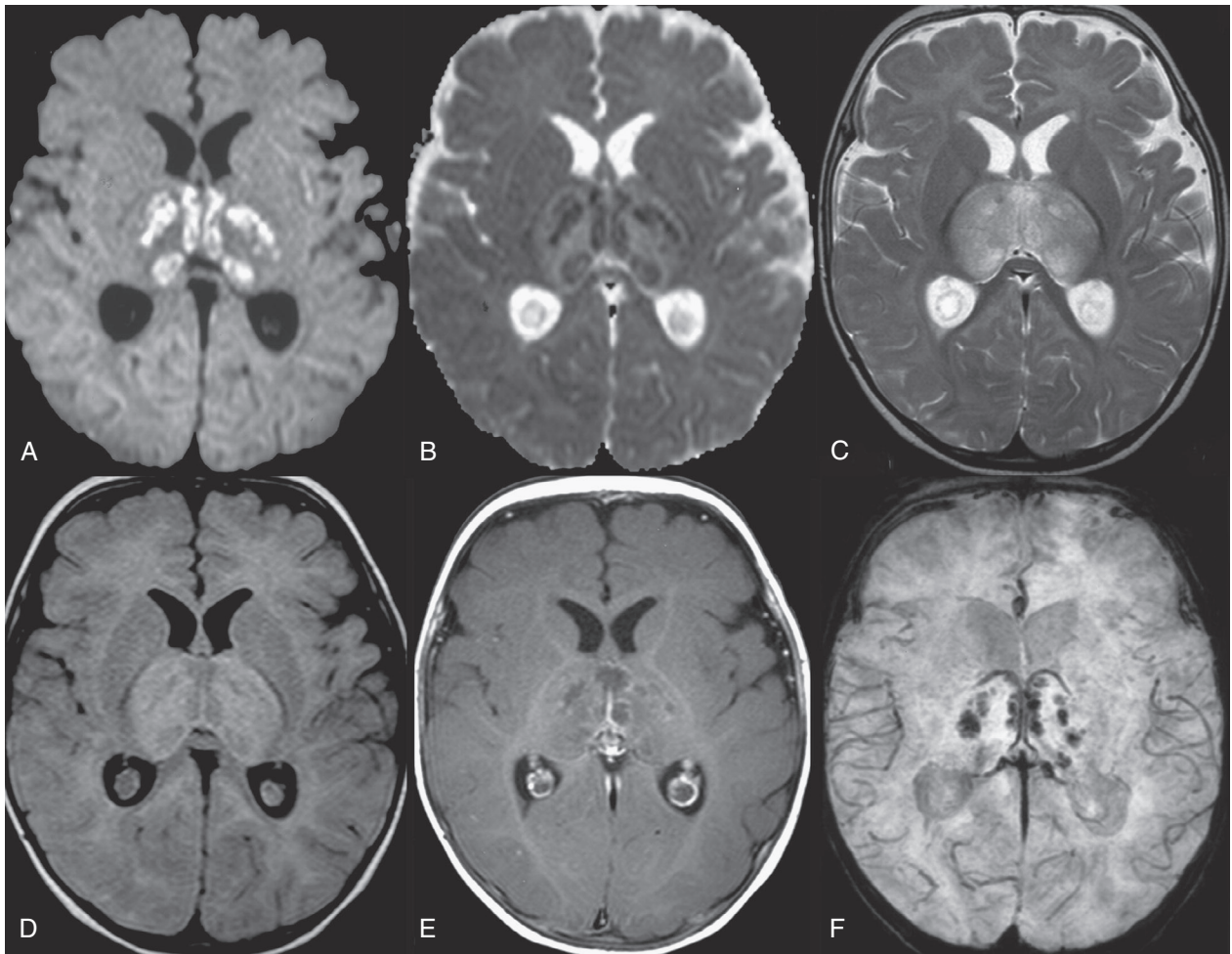Fig. 616.5 Acute necrotizing encephalopathy. MRI at presentation. **A**, Axial diffusion-weighted image; **B**, axial apparent diffusion coefficient (ADC) map; **C**, axial T2-weighted image; **D**, axial fluid-attenuated inversion recovery (FLAIR) image; **E**, contrast-enhanced axial T1-weighted image; **F**, axial susceptibility weighted image. Diffusion-weighted images (**A**) and corresponding ADC map (**B**) clearly show multiple areas of restricted diffusion against a background of increased diffusion involving both thalami, which are swollen. On T2-weighted (**C**) and FLAIR (**D**) images, the thalami are markedly swollen and hyperintense. On T1-weighted images obtained after intravenous gadolinium chelate injection (**E**), multiple necrotic portions are well delineated by peripheral faint, linear enhancement. Incidental choroid plexus cysts are detected. Susceptibility weighted image (**F**) shows multiple hypointense spots, consistent with petechial hemorrhage. (From Bergamino L, Capra V, Biancheri R, et al: Immunomodulatory therapy in recurrent acute necrotizing encephalopathy ANE1: is it useful? *Brain Dev* 34:384-391, 2012, Fig. 1.)

form is associated with mutations in the *RANBP2* gene and is designated ANE1. MRI findings are characterized by symmetric lesions that must be present in the thalami (Fig. 616.5). The prognosis is usually poor; however, some patients have responded to steroids and intravenous immunoglobulin (IVIG).

CYSTIC LEUKOENCEPHALOPATHY

An autosomal recessive disorder caused by mutations of *RNASET2* proteins produces a brain MRI study that closely resembles congenital cytomegalovirus infection. Cystic leukoencephalopathy is manifest as a static encephalopathy without megalencephaly.

Bibliography is available at Expert Consult.

616.4 Autoimmune Encephalitis

Thaís Armangué and Josep O. Dalmau

Autoimmune encephalitis comprises an expanding group of clinical syndromes that can occur at all ages (<1 yr to adult) but preferentially affect younger adults and children (Table 616.8). Some of these disorders

are associated with antibodies against neuronal cell surface proteins and synaptic receptors involved in synaptic transmission, plasticity, or neuronal excitability. The syndromes vary according to the associated antibody, with phenotypes that resemble those in which the function of the target antigen is pharmacologically or genetically modified.

Most of these disorders are severe and potentially fatal, but patients frequently respond to immunotherapy with good outcomes. Moreover, because of the broad spectrum of symptoms—including alterations of behavior, psychosis, catatonia, insomnia, memory deficits, seizures, abnormal movements, and autonomic dysregulation—patients usually require a multidisciplinary treatment approach, often in an intensive care unit.

The identification of these disorders provides a definitive diagnosis for many cases of encephalitis previously considered idiopathic, infectious, or postinfectious even though no causative agents were found. Because the etiology and pathogenic mechanisms were unknown, some of these disorders were previously defined with descriptive terms. More than half of cases under the ill-defined term encephalitis lethargica and some cases of choreoathetosis post-herpes simplex encephalitis are known to be anti-*N*-methyl-D-aspartate receptor (NMDAR) encephalitis.

The mechanisms that trigger the production of the antibodies are unknown. In a small subgroup of adolescent or young adult patients,

Bibliography

- Agarwal A, Kapur G, Altinok D: Childhood posterior reversible encephalopathy syndrome: magnetic resonance imaging findings with emphasis on increased leptomeningeal FLAIR signal, *Neuroradiol J* 28(6):638–643, 2015.
- Bergamino L, Capra V, Biancheri R, et al: Immunomodulatory therapy in recurrent acute necrotizing encephalopathy ANE1: is it useful?, *Brain Dev* 34:384–391, 2012.
- Britton PN, Dale RC, Blyth CC, et al: ACE study investigators and PAEDS network: Influenza-associated encephalitis/encephalopathy identified by the Australian childhood encephalitis study 2013–2015, *Pediatr Infect Dis J* 36(11):1021–1026, 2017.
- Donmez FY, Guleryuz P, Agildere M: MRI findings in childhood PRES: what is different than the adults?, *Clin Neuroradiol* 26(2):209–213, 2016.
- Gaynon PS, Angiolillo AL, Carroll WL, et al: Long-term results of the children's cancer group studies for childhood acute lymphoblastic leukemia 1983–2002: a children's oncology group report, *Leukemia* 24:285–297, 2010.
- Henneke M, Dickmann S, Ohlenbusch A, et al: RNASET2-deficient cystic leukoencephalopathy resembles congenital cytomegalovirus brain infection, *Nat Genet* 41:773–775, 2009.
- Hoshino A, Saitoh M, Oka A, et al: Epidemiology of acute encephalopathy in Japan, with emphasis on the association of viruses and syndromes, *Brain Dev* 34:337–343, 2012.
- Kastrup O, Gerwig M, Frings M, et al: Posterior reversible encephalopathy syndrome (PRES): electroencephalographic findings and seizure patterns, *J Neurol* 259:1383–1389, 2012.
- Lee VH, Wijidicks EFM, Manno EM, et al: Clinical spectrum of reversible posterior leukoencephalopathy syndrome, *Arch Neurol* 65:205–210, 2008.
- Loh NR, Appleton DB: Untreated recurrent acute necrotizing encephalopathy associated with RANBP2 mutation, and normal outcome in a caucasian boy, *Eur J Pediatr* 169:1299–1302, 2010.
- Morris B, Partap S, Yeom K, et al: Cerebrovascular disease in childhood cancer survivors: a Children's oncology group report, *Neurology* 73:1906–1913, 2009.
- Morris EB, Laningham FH, Sandlund JT, et al: Posterior reversible encephalopathy syndrome in children with cancer, *Pediatr Blood Cancer* 48:152–159, 2007.
- Neilson DE: The interplay of infection and genetics in acute necrotizing encephalopathy, *Curr Opin Pediatr* 22:751–757, 2010.
- Nielson DE, Adams MD, Orr C, et al: Infection-triggered familial or recurrent cases of acute necrotizing encephalopathy caused by mutation in a component of the nuclear pore, RANBP2, *Am J Hum Genet* 84:44–51, 2009.
- Onder AM, Lopez R, Teomete U, et al: Posterior reversible encephalopathy syndrome in the pediatric renal population, *Pediatr Nephrol* 22:1921–1929, 2007.
- Prasad N, Gulati S, Gupta RK, et al: Spectrum of radiological changes in hypertensive children with reversible posterior leukoencephalopathy, *Br J Radiol* 80:422–429, 2007.
- Wong AM, Simon EM, Zimmerman RA, et al: Acute necrotizing encephalopathy of childhood: correlation of MR findings and clinical outcome, *AJNR Am J Neuroradiol* 27:1919–1923, 2006.
- Yamamoto H, Natsume J, Kidokoro H, et al: Clinical and neuroimaging findings in children with posterior reversible encephalopathy syndrome, *Eur J Paediatr Neurol* 19(6):672–678, 2015.

Keywords

autoimmune
antibodies
encephalitis
NMDA receptor
GABAAR receptor
glutamic acid decarboxylase 65 (GAD65)
VGKC-complex
anti-NMDA receptor encephalitis
limbic encephalitis
acute disseminated encephalomyelitis (ADEM)
neuromyelitis optica spectrum disorder (NMOSD)
aquaporin 4
myelin oligodendrocyte glycoprotein (MOG)
Hashimoto encephalopathy
opsoclonus–myoclonus
Bickerstaff encephalitis
chronic lymphocytic inflammation with pontine perivascular
enhancement responsive to steroids (CLIPPERS)
Rasmussen encephalitis
fever-induced refractory epileptic encephalopathy syndrome (FIRES)
rapid-onset obesity with hypothalamic dysfunction, hypoventilation,
and autonomic dysregulation (ROHHAD)
basal ganglia encephalitis
pseudomigraine syndrome with CSF pleocytosis
headache with neurologic deficits and CSF lymphocytosis (HaNDL)
ophthalmoplegic migraine
recurrent cranial neuralgia
progressive encephalomyelitis with rigidity and myoclonus (PERM)

Table 616.8 Autoimmune Encephalitis in Children

DISEASE	ANTIBODIES AND/OR MECHANISMS	SYNDROME	ANCILLARY TEST	TREATMENT/PROGNOSIS
Anti-NMDAR encephalitis	Antibodies against the GluN1 subunit of the NMDAR. In children, most cases are idiopathic. In a subgroup of patients, the disease is triggered by the presence of a tumor. In another subgroup, the disease is triggered by HSV encephalitis.	Psychiatric symptoms, decreased verbal output, sleep disorder (mainly insomnia), seizures, dyskinesias (orofacial, limbs), dystonia, rigidity and other abnormal movements, autonomic dysfunction, hypoventilation	EEG: almost always abnormal (epileptic and/or slow activity). In some patients it shows the pattern of extreme delta brush. Brain MRI: nonspecific abnormal findings in ~ 35% CSF: pleocytosis and/or increased proteins in ~ 80%	80% substantial or complete recovery after immunotherapy and tumor removal (if appropriate). About 50% of patients need second-line immunotherapies.* Relapses in ~ 15% of patients. Worse outcome when post-HSE
Encephalitis associated with GABA _A R antibodies	Antibodies against $\alpha 1$, $\beta 3$, or $\gamma 2$ subunits of the GABA _A R. ~40% of adults have an underlying tumor (thymoma). Children usually do not have tumor association.	Refractory seizures, epilepsy partialis continua. Patients may develop limb or orofacial dyskinesias.	EEG: almost always abnormal; frequent epileptic activity MRI: multifocal corticosubcortical FLAIR/T2 hyperintensities in 77% of patients CSF: pleocytosis and/or increased proteins	80% show moderate or good recovery after immunotherapy.
Encephalitis with mGluR5 antibodies (Ophelia syndrome)	Antibodies against mGluR5 Frequent association with Hodgkin lymphoma	Abnormal behavior, seizures, memory deficits	EEG: frequently abnormal with nonspecific findings MRI: normal or nonspecific findings CSF: frequent pleocytosis and/or increased proteins	Good recovery after tumor treatment and immunotherapy
Other autoimmune encephalitis (very infrequent in children)	Antibodies against neuronal cell surface (GABA _B R, DPPX, GlyR) or intraneuronal antigens (Hu, Ma2, GAD65 amphiphysin) All these antibodies rarely associate with tumors in children.	The syndrome varies depending on the autoantibody, and the phenotypes are often different from those reported in adults. GABA _B R: encephalitis, seizures, cerebellar ataxia DPPX: CNS hyperexcitability, PERM GlyR: PERM or stiff person syndrome Hu: brainstem or limbic encephalitis Ma2: encephalitis, diencephalic encephalitis (only in adults) GAD65: limbic encephalitis, epilepsy	MRI: variable changes depending on the syndrome CSF: frequent pleocytosis and/or increased proteins	Disorders with antibodies against cell surface antigens are substantially more responsive to immunotherapy than those with antibodies against intracellular antigens.
ADEM	50–60% of patients with ADEM harbor MOG antibodies.	Seizures, motor deficits, ataxia, or visual dysfunction accompanied by encephalopathy	MRI with T2/FLAIR large, hazy abnormalities, with or without involvement of the deep gray matter CSF: frequent pleocytosis and/or increased proteins	In ~ 90% of patients, the disease is monophasic and shows good response to steroids. Some patients develop relapsing disease (with prolonged detection of MOG antibodies).
NMOSD	Patients can have AQP4 or MOG antibodies; some patients are seronegative.	Typical involvement of optic nerves and spinal cord Encephalopathy in the context of diencephalic or area postrema syndromes	Characteristic involvement of brain areas rich in AQP4 (periaqueductal gray matter, hypothalamus, optic nerve and central involvement of the spinal cord)	High risk of relapses and long-term disability. Requires chronic immunotherapy. Patients with MOG antibodies have better long-term outcome than those with AQP4 antibodies or seronegative cases.

Continued

Table 616.8 Autoimmune Encephalitis in Children—cont'd

DISEASE	ANTIBODIES AND/OR MECHANISMS	SYNDROME	ANCILLARY TEST	TREATMENT/PROGNOSIS
Opsoclonus–myoclonus and other cerebellar–brainstem encephalitis	Most patients do not have detectable autoantibodies (a few patients have Hu antibodies). Neuroblastoma occurs in 50% of children < 2 yr old; teratoma in teenagers and young adults.	Opsoclonus often accompanied by irritability, ataxia, falling, myoclonus, tremor, and drooling	MRI: usually normal; it may show cerebellar atrophy over time. EEG: Normal CSF: may be normal or show abnormalities suggesting B-cell activation	Neuroblastoma treatment (if it applies) Partial neurologic response to immunotherapy in many young children regardless of presence or absence of neuroblastoma. (Better outcomes if aggressive immunotherapy is used.) Good response to treatment in teenagers with teratoma-associated opsoclonus
Bickerstaff encephalitis	GQ1b antibodies (~65%, nonspecific for this disorder)	Ophthalmoplegia, ataxia, and decreased level of consciousness. Frequent hyperreflexia. Patients may develop hyporeflexia and overlap with Miller-Fisher syndrome.	MRI: abnormal in ~30% (T2-signal abnormalities in the brainstem, thalamus, and cerebellum) Nerve conduction studies: abnormal in ~ 45% (predominant axonal degeneration, and less often demyelination)	Good response to steroids, IVIG, or plasma exchange
Hashimoto encephalitis	TPO antibodies [†] (nonspecific for this disorder)	Stroke-like symptoms, tremor, myoclonus, aphasia, seizures, ataxia, sleep and behavioral problems	48% hypothyroidism, MRI often normal EEG: slow activity CSF: elevated protein	Steroid-responsive. Partial responses are frequent.
Rasmussen encephalitis	Most likely immune mediated (unclear mechanism)	Progressive refractory partial seizures, cognitive decline, focal deficits, and brain hemiatrophy	MRI: progressive unilateral hemispheric atrophy	Limited response to immunotherapy. Patients may need functional hemispherectomy
Basal ganglia encephalitis	Infrequent antibodies against D2R	Lethargy, abnormal movements, behavioral change, agitation, psychosis	MRI: Basal ganglia T2/FLAIR abnormalities, but may be normal in up to 50% CSF: frequently, elevated protein	Mostly monophasic, variable outcome. 40% complete recovery with immunotherapy.
CLIPPERS	No specific autoantibody association	Episodic diplopia or facial paresthesias with subsequent development of symptoms of brainstem and occasionally spinal cord dysfunction	MRI: symmetric curvilinear gadolinium enhancement peppering the pons and extending variably into the medulla, brachium pontis, cerebellum, midbrain, and, occasionally, spinal cord	Steroid-responsive but patients may require chronic steroid or other immunosuppressive therapy.
ROHHAD	Cause unknown, postulated autoimmune or genetic Frequently associated with neural crest tumors	Rapid-onset obesity, hyperphagia, abnormal behavior, autonomic dysfunction, and central hypoventilation	Brain MRI, usually normal	Symptomatic treatment. In some patients, limited response to immunotherapy

*Includes rituximab and cyclophosphamide.

[†]Diagnosis of exclusion, after ruling out relevant autoantibodies (e.g., NMDAR, AMPAR, among others).

AQP4, aquaporin 4; CLIPPERS, chronic lymphocytic inflammation with pontine perivascular enhancement responsive to steroids; CSF, cerebrospinal fluid; D2R, dopamine 2 receptor; DPPX, dipeptidyl-peptidase-like protein-6; EEG, electroencephalography; FLAIR, fluid-attenuated inversion recovery; GABAAR, γ -aminobutyric acid-A receptor; GABABR, γ -aminobutyric acid-B receptor; GAD65, glutamic acid decarboxylase 65; HSV, herpes simplex virus; IVIG, intravenous immunoglobulin; mGluR5, metabotropic glutamate receptor 5; MOG, myelin oligodendrocyte glycoprotein; MRI, magnetic resonance imaging; NMDAR, N-methyl-D-aspartate receptor; NMO/D, neuromyelitis optica spectrum disorder; PERM, progressive encephalomyelitis with rigidity and myoclonus; ROHHAD, rapid-onset obesity with hypothalamic dysfunction, hypoventilation, and autonomic dysregulation; TPO, thyroid peroxidase.

the presence of a tumor that expresses the target neuronal antigen likely contributes to the triggering of the immune response. In addition, the high prevalence of prodromal viral-like symptoms has suggested that nonspecific viral infections may contribute to breaking the immune tolerance for neuronal proteins and increasing the permeability of the blood–brain barrier to antibodies. Nonetheless, in many of these diseases the blood–brain barrier appears intact, and there is evidence that the autoantibodies are synthesized within the CNS by plasma cells that form part of the local brain and meningeal inflammatory infiltrates.

ANTI-N-METHYL-D-ASPARTATE RECEPTOR ENCEPHALITIS

In this disease, the immunoglobulin G antibodies target the GluN1 subunit of the NMDA receptor. The exact frequency of this disorder is unknown, but it is considered the second most common cause of autoimmune encephalitis after acute disseminated encephalomyelitis in children and adolescents. Overall, the disease predominates in females (80%), although in patients younger than 12 yr the frequency of males is higher (40%). The resulting syndrome is highly predictable and

usually evolves in stages. In teenagers and young adults, the disorder usually presents with prominent psychiatric manifestations that may include rapidly progressive anxiety, agitation, delusional thoughts, bizarre behavior, labile affect, mood disturbances (mania), catatonic features, memory deficit, language disintegration, aggression, and insomnia or other sleep disturbances. In many cases, these symptoms had been preceded by a few days of prodromal headache, fever, or viral infection–like symptoms. Patients are often misdiagnosed with new-onset psychosis or a primary psychiatric disorder. However, in a few days or weeks, additional symptoms occur, including a decreased level of consciousness, seizures (including status epilepticus), limb or oral dyskinesias, choreoathetoid movements, and autonomic instability that usually includes tachycardia, bradycardia, fluctuation of blood pressure, hyperventilation, hyperthermia, and sialorrhea. In rare instances, bradycardia and cardiac pauses occur, at times requiring the transient use of a pacemaker. The disorder also occurs in toddlers and infants (the youngest patient identified to date was 2 mo old), and although the evolution of the syndrome is similar to that of adults, young patients more frequently present with seizures and movement disorders. Because of the age of patients, the psychiatric-behavioral features may be missed. In this young age-group, behavior changes include irritability, new-onset temper tantrums, agitation, aggression, reduced speech, mutism, and autistic-like regression. Moreover, compared with adults, some children also develop cerebellar ataxia and hemiparesis; in contrast, autonomic dysfunction is usually milder and less severe in children.

Brain MRI studies are abnormal in approximately 35% of patients, usually showing nonspecific cortical and subcortical T2–fluid-attenuated inversion recovery (FLAIR) signal abnormalities, sometimes with transient cortical or meningeal enhancement; nonspecific white matter abnormalities can occur. However, if white matter changes are predominant, an overlapping syndrome should be suspected (Figs. 616.6 and 616.7). The cerebrospinal fluid (CSF) is initially abnormal in approximately 80% of patients, showing moderate lymphocytic pleocytosis and, less frequently, increased protein synthesis and oligoclonal bands. The electroencephalogram (EEG) is abnormal in virtually all patients,

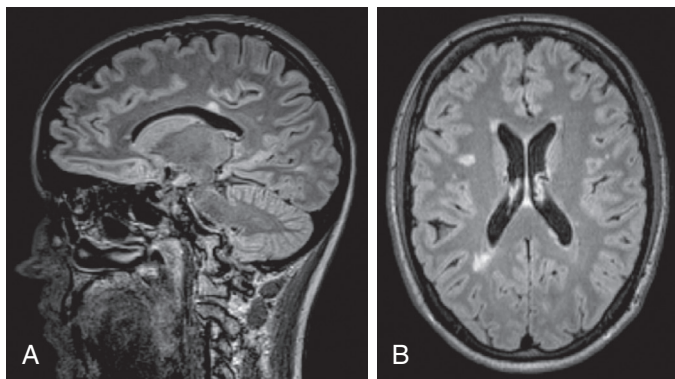


Fig. 616.6 Overlapping demyelinating syndrome in two patients with NMDAR encephalitis. **A**, FLAIR-hyperintense lesions in the corpus callosum of a 20 yr old female patient with NMDAR encephalitis, one lesion with a “Dawson finger” aspect typical of multiple sclerosis. Further demyelinating lesions were observed in the periventricular white matter, with two of the lesions showing contrast enhancement. Lesions were detected on a routine follow-up MRI; however, the patient had suffered from fatigue during the last 6 mo before the MRI. Shortly after the MRI, she developed hypoesthesia of both lower legs and bladder dysfunction. A treatment with intravenous steroids was initiated, and symptoms partially remitted. **B**, FLAIR-hyperintense lesions in the periventricular white matter of a 26 yr old female patient with NMDAR encephalitis. In total, 14 supratentorial lesions were detected, and two lesions showed contrast enhancement. MRI was performed because the patient had reported intermittent double vision. The patient was treated with intravenous steroids, and the double vision remitted. (From Heine J, Pruss H, Bartsch T, et al: *Imaging of autoimmune encephalitis: relevance for clinical practice and hippocampal function*. *Neuroscience* 309:68-83, 2015, Fig. 3.)

and it usually shows focal or diffuse slow activity in the delta and theta ranges, which does not correlate with abnormal movements. In addition, many patients develop epileptic activity, requiring video monitoring for adequate clinical management. A characteristic EEG pattern called extreme delta brush, characterized by beta–delta complexes, occurs in 30% of adults and has been described in children (Fig. 616.8).

The diagnosis of the disorder is established by demonstrating NMDAR antibodies in CSF and serum. The sensitivity is higher in CSF compared with serum (100% vs 85%), and the levels of antibodies in CSF appear to correlate better with the outcome. Antibodies may remain detectable, albeit at lower titers, after patients recover.

The presence of an underlying tumor, usually a teratoma, is age and sex dependent. Whereas 40% of females older than 12 yr have an underlying teratoma of the ovary, the presence of a tumor is exceptional in young males and females or young adult male patients. In children, an MRI of the abdomen and pelvis and abdominal and testicular ultrasound are the preferred tumor screening tests.

In a small number of patients, anti-NMDAR encephalitis occurs simultaneously with or after infections with a variety of pathogens, including *Mycoplasma pneumoniae*, herpes simplex virus 1 (HSV1), human herpes virus 6, enterovirus, and influenza virus. With the exception of HSV1, a pathogenic link with most of these infections has not been established. There is evidence that some patients with HSV encephalitis develop antibodies against the GluN1 subunit of the NMDAR and other neuronal cell surface proteins and receptors, which leads to the presentation of new or relapsing neurologic symptoms 2–12 wk after completing treatment for HSV encephalitis. In children younger than 4 yr, this type of autoimmune encephalitis usually manifests with choreoathetosis and dyskinesias (known as choreoathetosis post-HSV encephalitis; see **Videos 616.1, 616.2, and 616.3**). In contrast, older children and adults more often develop predominantly behavioral symptoms.

Although no prospective clinical trials have been done, there is evidence that tumor removal, when appropriate, and prompt immunotherapy improve the outcome. Most children receive first-line immunotherapies, including corticosteroids, IVIG, or plasma exchange. However, because these treatments fail in almost 50% of patients, and with an increasing number of reports showing that rituximab can be effective, this treatment is increasingly being used in combination with IVIG and steroids or after first-line immunotherapies. Cyclophosphamide can be effective when there has been no response to these treatments.

Although anti-NMDAR encephalitis has a mortality rate of 7%, approximately 80% of patients recover substantially or fully. Recovery is usually slow and can take as long as 2 yr after symptom onset. The last symptoms to improve are problems in social interactions and language and executive functions. Relapses occur in approximately 15% of patients; they can develop as partial syndromes, are usually milder than the initial episode, and respond equally well to immunotherapy. Initial comprehensive immunotherapy appears to prevent or reduce the number of relapses. The efficacy of chronic immunosuppression with drugs such as azathioprine or mycophenolate mofetil in preventing relapses is unknown.

The differential diagnosis of anti-NMDAR encephalitis is extensive and varies according to the stage of the disease (Table 616.9). The most frequently considered disorders are viral encephalitis, neuroleptic malignant syndrome, acute psychosis, and drug abuse.

OTHER TYPES OF ENCEPHALITIS ASSOCIATED WITH ANTIBODIES AGAINST NEURONAL CELL SURFACE ANTIGENS

Encephalitis with antibodies against the γ -aminobutyric acid A receptor (GABA_AR) is a rare autoimmune encephalitis that can affect children (40% of patients < 18 yr) and develops with status epilepticus, refractory seizures, or epilepsy partialis continua in association with antibodies against the $\alpha 1$, $\beta 3$, or $\gamma 2$ subunits of the GABA_AR. Young children can develop abnormal movements suggesting anti-NMDAR encephalitis but with studies negative for NMDAR antibodies. Unlike other types of autoimmune encephalitis in which the brain MRI is usually normal or shows nonspecific findings, adult and pediatric patients with this disorder frequently develop multifocal hyperintense cortical-subcortical

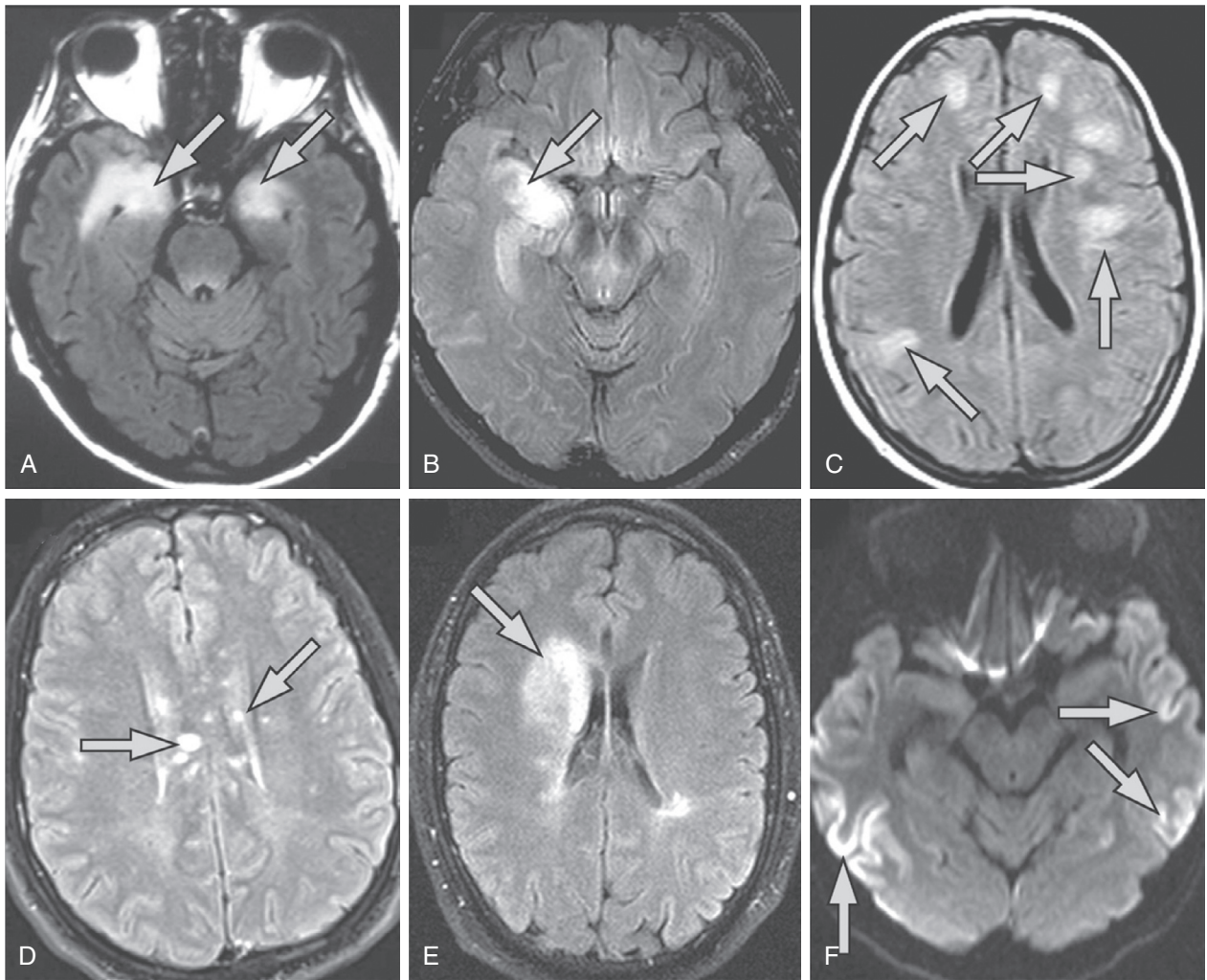


Fig. 616.7 MRI patterns in autoimmune encephalitis and its mimics. Typical MRI of limbic encephalitis (**A**) with bilateral abnormalities in the medial temporal lobe on T2-weighted fluid-attenuated inversion recovery imaging; this patient with autopsy-proven limbic encephalitis did not have serum or CSF antineuronal antibodies. Patient with final diagnosis of glioma (**B**) who presented with unilateral right hippocampal involvement mimicking limbic encephalitis. Typical MRI of acute disseminated encephalomyelitis (**C**) with bilateral large lesions in the white matter. Multiple lesions involving the corpus callosum in a patient with Susac syndrome (**D**). MRI of a patient with overlapping syndrome (NMDA receptor and myelin oligodendrocyte glycoprotein antibodies) (**E**) showing a right frontal abnormality compatible with demyelination. Diffusion MRI sequence in a patient with AMPA receptor antibody-associated encephalitis (**F**) mimicking MRI changes seen in patients with Creutzfeldt-Jakob disease. Left side of images = right side of brain. (From Graus F, Titulaer MJ, Balu R, et al: A clinical approach to diagnosis of autoimmune encephalitis, *Lancet Neurol* 15:391-404, 2016, Fig. 2.)

Fig. 616.8 Electroencephalogram showing a pattern called extreme delta brush in a 14 yr old girl with anti-N-methyl-D-aspartate receptor (NMDAR) encephalitis. This pattern has been found to be characteristic of anti-NMDAR encephalitis. It consists of a nearly continuous combination of delta activity with superimposed fast activity, usually in the beta range, symmetrically involving all regions, with a frontal preference in patients who are not under sedation or anesthesia. (From Armangue T, Titulaer MJ, Málaga I, et al: Pediatric anti-N-methyl-D-aspartate receptor encephalitis: clinical analysis and novel findings in a series of 20 patients, *J Pediatr* 162:850-856, 2012, Fig. 2.)

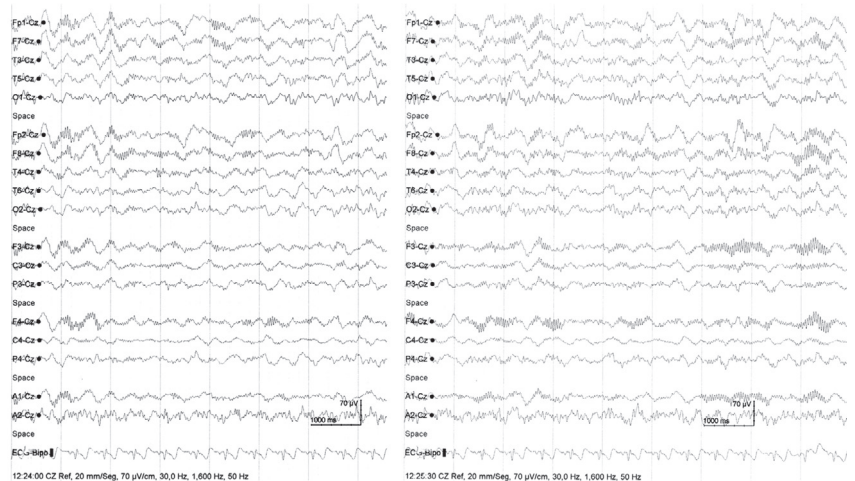


Table 616.9 Differential Diagnosis of Anti-NMDAR and Other Types of Autoimmune Encephalitis in Children

DISORDER	COMMENTS
Viral encephalitis	Viral encephalitis is often suggested by the acute onset of symptoms, CSF pleocytosis, and hyperthermia. Most viral encephalitides (except rabies) occur with higher levels of CSF pleocytosis and protein concentration. Psychosis and dyskinesias are significantly less frequent in viral encephalitis than in anti-NMDAR encephalitis.
Relapsing post-herpes simplex virus encephalitis	Occurs ~ 2-12 wk after successful treatment of herpes simplex encephalitis. This may represent a true viral relapse of encephalitis (CSF PCR-positive, progression of necrotic MRI changes, response to acyclovir) or an autoimmune disorder (CSF PCR-negative, no new necrotic lesions on MRI, lack of response to acyclovir). In a proportion of the latter patients, the disorder is anti-NMDAR encephalitis.
New-onset psychosis	Because most patients with anti-NMDAR encephalitis present with psychosis, a psychiatric disorder is frequently considered. As the disease evolves, the development of neurologic symptoms usually reveals the diagnosis.
Drugs/toxins	The acute development of personality and behavioral changes and symptoms suggesting involvement of dopaminergic pathways (rigidity, dystonia, orofacial movements) usually leads to a suspicion of drug abuse (e.g., ketamine, phencyclidine, among others).
Neuroleptic malignant syndrome	The occurrence of an altered level of consciousness, episodes of rigidity, hyperthermia, and autonomic instability often suggest NMS. In addition, some patients with anti-NMDAR encephalitis have elevated serum creatine kinase and rhabdomyolysis (in the absence of antipsychotic medication). The frequent use of neuroleptics to control the abnormal behavior adds further confusion between both syndromes. The presence of dyskinesias and catatonia suggest anti-NMDAR encephalitis.
Limbic encephalitis	Criteria of LE are well defined. Patients with LE do not have dyskinesias or central hypoventilation; the MRI usually shows abnormalities restricted to the medial temporal lobes, and the EEG findings (epileptic or slow activity) are largely restricted to the temporal lobes.
Encephalitis lethargica	This is an ill-defined entity, likely representing multiple disorders. Criteria include acute or subacute encephalitis with at least three of the following: signs of basal ganglia involvement; oculogyric crises; ophthalmoplegia; obsessive-compulsive behavior; akinetic mutism; central respiratory irregularities; and somnolence and/or sleep inversion. Many patients categorized as encephalitis lethargica hyperkinetica have anti-NMDAR encephalitis.
Childhood disintegrative disorder/late-onset autism	Children with anti-NMDAR encephalitis often show cognitive regression, rapid loss of language function, autistic features, and seizures, suggesting a childhood disintegrative disorder. Although the prognosis of CDD is poor, most patients with anti-NMDAR encephalitis respond to immunotherapy and have a substantial clinical recovery.
Kleine-Levin syndrome	Symptoms of hypersomnia, compulsive hyperphagia, hypersexuality, apathy, and child-like behavior, which are typical components of Kleine-Levin syndrome, may occur transiently during the process of recovery of anti-NMDAR encephalitis, or as permanent sequelae.
Inborn errors of metabolism	Glutaric aciduria type I can present in previously asymptomatic patients as episodes of encephalopathy with dystonia, coinciding with an infection or febrile process. Several inborn errors of metabolism can also occur with acute or subacute encephalopathy with extrapyramidal signs, including 3-methylglutaconic aciduria, creatine transport deficiency, mitochondrial disorders (Leigh syndrome), Wilson syndrome, and Lesch-Nyhan syndrome. Pantothenate kinase-associated neurodegeneration, porphyria, and urea cycle defects should also be considered.
Genetic disorders that can manifest as autoimmune encephalitis	HLH, RANBP2 mutations, interferonopathies, autoinflammatory syndromes including cryopyrin-associated periodic syndromes, and CTLA4 deficiency can present with clinical features mimicking ADEM or autoimmune or infectious encephalitis. MRI often shows hyperintense T2/FLAIR abnormalities involving white matter with contrast enhancement in HLH and CTLA4 deficiency; both thalami in RANBP2 mutations; and may show striatal necrosis with or without associated hypomyelination in ADAR1 interferonopathy. CSF is abnormal in most patients. Some patients develop systemic symptoms (e.g., fever, arthralgias or rash in autoinflammatory syndromes, or autoimmune cytopenias or hypogammaglobulinemia in CTLA4 deficiency) that can help to make the diagnosis, which is confirmed by genetic testing.
Monoamine neurotransmitter disorders	Deficiency of dopamine or serotonin, or both, can result in encephalopathy, epilepsy, and pyramidal and extrapyramidal symptoms. The diagnosis is established by examining the CSF for levels of these neurotransmitters.
Acquired demyelinating disorders	ADEM and NMOSD are immune-mediated inflammatory and demyelinating disorders of the central nervous system. These disorders should be considered in the differential diagnosis of multifocal neurologic abnormalities and encephalopathy in children. As with anti-NMDAR encephalitis, these disorders may be preceded by an infection and can show pleocytosis. The diagnosis is suggested by the MRI findings. In NMOSD, the presence of AQP4 antibodies in serum or CSF is associated with relapses and poor prognosis. MOG antibodies occur in ~ 50% of children with ADEM and some patients with NMOSD.
CNS vasculitis	CNS vasculitis results in neurologic deficits and psychiatric manifestations. The diagnosis is established by angiography in large-vessel angiitis and brain biopsy in small-vessel angiitis. In the latter, serum inflammatory markers (erythrocyte sedimentation rate, C-reactive protein, Complement 3, von Willebrand factor antigen) are usually elevated, and the MRI shows FLAIR/T2 abnormalities in the white and/or gray matter suggesting ischemia and microhemorrhages, but are not restricted to vascular territories and frequent leptomeningeal and/or local enhancement.
Systemic rheumatic disorders	Systemic lupus erythematosus and other rheumatic disorders can result in encephalopathy and multifocal neurologic and psychiatric manifestations. These disorders are usually suggested by the presence of signs and symptoms of involvement of systemic organs: skin, joints, kidneys, blood-forming cells, and blood vessels.

ADEM, acute disseminated encephalomyelitis; AQP4, aquaporin 4; CDD, childhood disintegrative disorder; CNS, central nervous system; CSF, cerebrospinal fluid; EEG, electroencephalography; FLAIR, fluid-attenuated inversion recovery; HLH, hemophagocytic lymphohistiocytosis; LE, limbic encephalitis; MOG, myelin oligodendrocyte glycoprotein; MRI, magnetic resonance imaging; NMDAR, N-methyl-D-aspartate receptor; NMOSD, neuromyelitis optica spectrum disorders; NMS, neuroleptic malignant syndrome; PCR, polymerase chain reaction; RANBP2, Ras-related nuclear protein-binding protein 2; CTLA4, cytotoxic T-lymphocyte-associated protein 4; ADAR1, adenosine deaminase acting on RNA 1.

FLAIR/T2 abnormalities. In adults, this encephalitis may occur with thymoma, but children rarely have an underlying tumor.

The **Ophelia syndrome** is a form of encephalitis that occurs in association with Hodgkin lymphoma and predominantly affects young adults, teenagers, or children. Some patients develop antibodies against mGluR5, a receptor involved in learning and memory. Neurologic symptoms are highly responsive to treatment of the tumor and immunotherapy.

Autoimmune limbic encephalitis refers to an inflammatory process of the limbic system, including the medial temporal lobes, amygdala, and cingulate gyri. In adults, the most frequent immune-mediated limbic encephalitis occurs in association with antibodies against proteins that were once thought to be voltage-gated potassium channels (VGKCs) but which, in fact, target a secreted neuronal protein called leucine-rich glioma-inactivated 1 (LGI1) and a protein called Caspr2 expressed in the brain and the juxtaparanodal regions of myelinated nerves. Patients with LGI1 antibody-associated limbic encephalitis often develop *hyponatremia*; in some patients, the disorder is preceded by dystonic or myoclonic-like movements, described as *faciobrachial dystonic seizures*. Patients with Caspr2 antibodies can develop limbic encephalitis, neuromyotonia, or **Morvan syndrome**, which includes encephalopathy, seizures, a sleep disorder, autonomic dysfunction, and neuromyotonia. Studies have demonstrated that in patients without LGI1 or Caspr2 antibodies, the detection of VGKC-complex antibodies has very limited clinical significance. In children, the identification of LGI1 or Caspr2 antibodies is unusual; therefore, a positive test for VGKC-complex antibodies should be interpreted with caution because it does not necessarily indicate autoimmune encephalitis. In children, autoimmune or paraneoplastic limbic encephalitis is exceptional. Unfortunately, any type of encephalopathy resulting in seizures and alteration of memory and behavior is often labeled as limbic encephalitis, making data based on literature searches using the term *limbic encephalitis* unreliable. Excluding patients with NMDAR or GABAAR antibody-associated encephalitis, fewer than 30 children with limbic and other types of antibody-associated encephalitis have been reported in the English literature, some of them with antibodies against neuronal cell surface receptors or proteins (GABA_BR, DPPX, GlyR), intracellular proteins (Hu, Ma2, GAD65, amphiphysin), or intracellular proteins of unknown identity (VGKC-complex proteins). In some patients, an underlying tumor was identified, including leukemia, ganglioneuroblastoma, neuroblastoma, or small-cell carcinoma of the ovary.

In practice, determination of the type of autoantibodies and location of the target antigens is important because an encephalitis in which the antigens are on the cell surface (e.g., NMDAR or GABAAR) responds better to immunotherapy than one in which the antigens are intracellular (e.g., GAD65).

ACQUIRED DEMYELINATING SYNDROMES WITH ENCEPHALOPATHY

Acute disseminated encephalomyelitis (ADEM) is the most frequent autoimmune encephalitis in children (see Chapter 618.4). Symptoms may include seizures, motor deficits, ataxia, and visual dysfunction, among others. Antibodies against myelin oligodendrocyte glycoprotein (MOG) occur in 50–60% of patients with ADEM and have a negative predictive value for evolution to multiple sclerosis in children with a first demyelinating event (see Chapter 618.4). MOG antibodies have also been described in patients with autoimmune encephalitis and MRI findings showing predominant gray matter involvement (cortex and deep gray matter structures).

Neuromyelitis optica spectrum disorder (NMOSD) can present as an encephalopathy with predominant involvement of diencephalic and area postrema regions. These patients often harbor aquaporin 4 (AQP4) antibodies or MOG antibodies. Determination of these antibodies should be considered in patients with encephalopathy and MRI findings showing involvement of AQP4-rich regions, such as the periaqueductal gray matter, hypothalamus, optic nerves, and central region of the spinal cord (see Chapter 618.2).

HASHIMOTO ENCEPHALOPATHY

Hashimoto encephalopathy, or more appropriately, steroid-responsive encephalopathy with autoimmune thyroiditis (SREAT), is defined by the

detection of thyroid peroxidase (TPO) antibodies in patients with acute or subacute encephalitis that responds to corticosteroids. Clinical features are not specific and may include stroke-like episodes, tremor, myoclonus, transient aphasia, sleep and behavior abnormalities, hallucinations, seizures, and ataxia. The CSF usually shows an elevated protein level with less frequent pleocytosis. EEG studies almost always are abnormal, frequently showing generalized slowing. A brain MRI is usually normal, although it may show diffuse white matter abnormalities and meningeal enhancement that can resolve with steroid therapy. Because TPO antibodies occur in approximately 10% of asymptomatic children (i.e., those who are nonencephalopathic and, in most cases, euthyroid) and can also be found in some patients who have more relevant antibody-associated diseases, the detection of TPO antibodies should be viewed as a marker of autoimmunity rather than a disease-specific or pathogenic antibody. Therefore, the presence of TPO antibodies should not prevent testing for more relevant antibodies, such as NMDAR antibodies.

OPSOCLONUS-MYOCLONUS AND OTHER TYPES OF BRAINSTEM-CEREBELLAR ENCEPHALITIS

Opsoclonus–myoclonus occurs in infants, teenagers, and adults, although it probably represents different diseases and pathogenic mechanisms. In infants, the syndrome usually develops in the first 2 yr of life (mean: 20 mo), and at least 50% of patients have an underlying neuroblastoma. The child often presents with irritability, ataxia, falling, myoclonus, tremor, and drooling. Additional symptoms may include a refusal to walk or sit, speech problems, hypotonia, and the typical features of opsoclonus characterized by rapid, chaotic, multidirectional eye movements without saccadic intervals. Because opsoclonus may be absent at symptom presentation, patients may initially be diagnosed with acute cerebellitis or labyrinthitis. Typically, CSF abnormalities suggest B-cell activation, and the presence of antibodies against neuronal proteins has been demonstrated in some patients, although the identification of a specific autoantigen has been elusive.

Immunotherapy, including corticosteroids and IVIG, often improves the abnormal eye movements, but residual behavioral, language, and cognitive problems persist in the majority of patients, often requiring special education. In addition, insomnia and an abnormal response to pain are common. Relapses occur in 50% of patients, usually as a result of an intercurrent infection or drug tapering. Patients treated with more aggressive immunosuppression (often including rituximab) have better outcomes compared with historic control series or patients who did not receive these treatments. Delay in treatment appears to be associated with a poorer neurologic outcome; therefore, in cases with neuroblastoma, removal of the tumor should not delay the start of immunotherapy.

In teenagers and young adults, opsoclonus–myoclonus and brainstem–cerebellar encephalitis without opsoclonus are often considered idiopathic or postinfectious; however, there is evidence that some of these patients have an underlying **teratoma**, usually in the ovaries. These patients do not harbor NMDAR antibodies, and compared with those with anti-NMDAR encephalitis, they are less likely to present with psychosis and behavioral changes and rarely develop dyskinesias. Although these patients do not appear to have neuronal antibodies, the CSF often shows pleocytosis and an elevated protein concentration. Identification of this subphenotype of opsoclonus–myoclonus is important because patients usually have full recovery after treatment with immunotherapy (corticosteroids, IVIG, and/or plasma exchange) and removal of the ovarian teratoma if it is present. The prognosis of opsoclonus–myoclonus in teenagers and young adults seems better than that of young children (with or without neuroblastoma) or of the paraneoplastic opsoclonus of older patients, usually related to breast, ovarian, or lung cancer.

BICKERSTAFF ENCEPHALITIS

This term is used to describe patients with rapid progression (<4 wk) of bilateral external ophthalmoplegia, ataxia, and decreased level of consciousness. Although this entity has been described more frequently in adults, children as young as 3 yr old have been identified. Most patients are treated with steroids, IVIG, or plasma exchange, and they often have a good outcome. Serum GQ1b immunoglobulin G antibodies are found in 66% of patients. Brain MRI abnormalities occur in 30% of patients and usually include increased T2-signal abnormalities in

the brainstem, thalamus, and cerebellum and sometimes in the cerebral white matter. Some patients develop hyporeflexia and limb weakness, with predominant axonal involvement, overlapping with symptoms of the Miller–Fisher syndrome and the axonal subtype of the Guillain–Barré syndrome.

CHRONIC LYMPHOCYTIC INFLAMMATION WITH PONTINE PERIVASCULAR ENHANCEMENT RESPONSIVE TO STEROIDS

CLIPPERS is a clinically and radiologically distinct pontine-predominant encephalomyelitis. Patients usually present with episodic diplopia or facial paresthesias with subsequent development of symptoms of brainstem and, occasionally, spinal cord dysfunction. A brain MRI shows symmetric curvilinear gadolinium enhancement peppering the pons and extending variably into the medulla, brachium pontis, cerebellum, and midbrain and occasionally into the spinal cord. The clinical and radiologic findings usually respond to high-dose steroids but may worsen after steroid tapering, requiring chronic steroid or other immunosuppressive therapy. The differential diagnosis is extensive and includes infections, acquired demyelinating syndromes, granulomatous disease, lymphoma, or vasculitis. Biopsy studies may be needed to exclude these and other conditions.

AUTOIMMUNE ENCEPHALOPATHIES ASSOCIATED WITH EPILEPSY AND STATUS EPILEPTICUS

Rasmussen encephalitis is an inflammatory encephalopathy characterized by progressive refractory focal seizures, cognitive deterioration, and focal neurologic deficits that occur with gradual atrophy of one brain hemisphere. The disorder frequently presents in children 6–8 yr old, although adolescents and adults can be affected. The etiology is unknown, and, therefore, multiple theories are proposed, including the presence of neuronal antibodies and T-cell-mediated mechanisms triggered by a viral infection. None of these mechanisms satisfactorily explain the unilateral brain involvement characteristic of the disorder. Treatment with high-dose steroids, plasma exchange, or IVIG can ameliorate symptoms in early stages of the disease. Rituximab and intraventricular γ -interferon have been effective in a few isolated cases. In a small series, patients treated with tacrolimus showed better outcomes of neurologic function and slower progression of cerebral hemiatrophy but did not have improved seizure control. An open-label study using a monoclonal antibody against tumor necrosis factor (TNF)- α (adalimumab) led to seizure control and preservation of cognitive function in approximately 50% of patients. The most effective treatment for control of the seizures is functional hemispherectomy, which consists of surgical disconnection of the affected hemisphere.

The discovery of treatment-responsive encephalitis associated with antibodies against cell surface or synaptic proteins has suggested that there may be an autoimmune basis for several devastating encephalopathies with refractory seizures. Some well-defined types of autoimmune encephalitis, such as anti-NMDAR or GABA_AR encephalitis, can present with refractory seizures or status epilepticus. Most of these patients develop other clinical features that suggest the diagnosis of the disease, and testing for the corresponding antibodies leads to the correct diagnosis and initiation of immunotherapy.

A devastating epileptic encephalopathy associated with fever named **fever-induced refractory epileptic encephalopathy syndrome (FIRES)**, among other terms, is suspected to be an infection-triggered autoimmune process because of its biphasic clinical course and the occasional finding of neuronal antibodies in a few patients. However, the lack of response to most treatments, including immunotherapy, and the rare and inconsistent association with different types of antibodies have cast doubts on an autoimmune pathogenesis. Some investigators suggest a genetic error in metabolism.

Antibodies to VGKC-complex proteins different from LGI1 and Caspr2 have been described in some children with encephalitis with or without status epilepticus. Given that the target antigens are most

likely intracellular and the response to immunotherapy is unpredictable, the significance of these antibodies is unclear.

OTHER SUSPECTED TYPES OF AUTOIMMUNE ENCEPHALITIS

Vasculitis of the CNS and rheumatic diseases associated with autoimmune mechanisms that can result in encephalitis are discussed in Chapter 620.

Rapid-onset obesity with hypothalamic dysfunction, hypoventilation, and autonomic dysregulation (ROHHAD; see also Chapter 60.1) usually affects children who had normal development until 2–4 yr of age and then developed a rapid onset of hyperphagia, weight gain, and abnormal behavior (social disinhibition, irascibility, impulsivity, lethargy, outburst of euphoria and laughing, impaired concentration), followed by autonomic dysfunction (abnormal pupillary responses, thermal dysregulation, gastrointestinal dysmotility) and central hypoventilation. An autoimmune or paraneoplastic etiology of ROHHAD syndrome is supported by the frequent association with neural crest tumors, the identification in some patients of genetic factors predisposing them to autoimmunity, and the finding in some patients of intrathecal oligoclonal bands and infiltrates of lymphocytes and histiocytes in the hypothalamus. Furthermore, responses to immunotherapy have been described in a few patients. A possible genetic origin is suggested because of the similarities of this syndrome with the congenital central hypoventilation syndrome (Ondine curse) related to a *PHOX2B* mutation, which presents in the neonatal period and is also associated with autonomic problems (Hirschsprung disease) and neural crest tumors (see Chapter 446.2). However, no mutations in *PHOX2B* and other candidate genes have been found in patients with ROHHAD.

The term **basal ganglia encephalitis** is used to describe patients with predominant or isolated involvement of the basal ganglia. These patients typically have abnormal movements and neuropsychiatric disease. Although these clinical manifestations may have multiple etiologies, including metabolic, toxic, genetic, and infectious processes, an immune-mediated etiology has been postulated in some patients. There have been no clinical trials, but case reports and small noncontrolled case series describe the potential benefit of immunotherapy. Antibodies against the dopamine-2 receptor have been infrequently identified in these patients, as well as in patients with Sydenham chorea and Tourette syndrome.

Pseudomigraine syndrome with CSF pleocytosis (PMP) or headache with neurologic deficits and CSF lymphocytosis (HaNDL) is an ill-defined entity that predominantly affects young male adults with a family history of migraine, although adolescents can be affected. This syndrome is characterized by repeat episodes of severe headache with transient neurologic deficits, accompanied by aseptic CSF lymphocytosis and a normal brain MRI. Patients frequently show a high CSF opening pressure, an elevated CSF protein concentration, and focal EEG slowing, which normalize after the episodes of headache. Because of the inflammatory characteristics of the CSF and the high prevalence of prodromal viral-like symptoms, an infectious–autoimmune-mediated mechanism has been proposed. Other theories include spreading cortical depression and trigeminal-vascular activation.

An immune-mediated mechanism and trigeminal-vascular activation are also considered as possible mechanisms of **ophthalmoplegic migraine**, also named **recurrent cranial neuralgia**. This disorder predominantly affects young children and is characterized by recurrent bouts of headache in addition to palsy of cranial nerves III, IV, and/or VI. In contrast to PMP/HaNDL, CSF studies do not show pleocytosis, and in approximately 75% of patients, the MRI shows focal nerve thickening and contrast enhancement. Observational data suggest that treatment with steroids may be beneficial. In this syndrome, as well as in PMP/HaNDL, the differential diagnosis includes structural, neoplastic, traumatic, metabolic, and infectious disorders.

Bibliography is available at Expert Consult.

Bibliography

- Amrom D, Kinay D, Hart Y, et al: Rasmussen encephalitis and comorbid autoimmune diseases, *Neurology* 83:1049–1055, 2014.
- Ariño H, Armangué T, Petit-Pedrol M, et al: Anti-LGI1-associated cognitive impairment: presentation and long-term outcome, *Neurology* 87:759–765, 2016.
- Armangue T, Spatola M, Vlasea A, et al: Frequency, symptoms, risk factors, and outcomes of autoimmune encephalitis after herpes simplex encephalitis: a prospective observational study and retrospective analysis, *Lancet Neurol* 17:760–772, 2018.
- Armangue T, Titulaer MJ, Málaga I, et al: Pediatric anti-N-methyl-D-aspartate receptor encephalitis—clinical analysis and novel findings in a series of 20 patients, *J Pediatr* 162:e850.e2–856.e2, 2012.
- Armangue T, Titulaer MJ, Sabater L, et al: A novel treatment-responsive encephalitis with frequent opsoclonus and teratoma, *Ann Neurol* 75:850–856, 2014.
- Bien CG, Franata T, Antozzi C, et al: Pathogenesis, diagnosis and treatment of rasmussen encephalitis: a European consensus statement, *Brain* 128:454–471, 2005.
- Brenton JN, Goodkin HP: Antibody-mediated autoimmune encephalitis in childhood, *Pediatr Neurol* 60:13–23, 2016.
- Crow YJ: Type I interferonopathies: mendelian type I interferon up-regulation, *Curr Opin Immunol* 32:7–12, 2015.
- Dale RC, Brilot F, Duffy LV, et al: Utility and safety of rituximab in pediatric autoimmune and inflammatory CNS disease, *Neurology* 83:142–150, 2014.
- Dale RC, Merheb V, Pillai S, et al: Antibodies to surface dopamine-2 receptor in autoimmune movement and psychiatric disorders, *Brain* 135:3453–3468, 2012.
- Dalmau J, Geis C, Graus F: Autoantibodies to synaptic receptors and neuronal cell-surface proteins in autoimmune diseases of the central nervous system, *Physiol Rev* 97(2):839–887, 2017.
- Dalmau J, Gleichman AJ, Hughes EG, et al: Anti-NMDA-receptor encephalitis: case series and analysis of the effects of antibodies, *Lancet Neurol* 7:1091–1098, 2008.
- Dalmau J, Graus F: Antibody-mediated encephalitis, *N Engl J Med* 378(9):840–851, 2018.
- Dalmau J, Lancaster E, Martinez-Hernandez E, et al: Clinical experience and laboratory investigations in patients with anti-NMDAR encephalitis, *Lancet Neurol* 10:63–74, 2011.
- Deiva K, Mahlaoui N, Beaudonnet F, et al: CNS involvement at the onset of primary hemophagocytic lymphohistiocytosis, *Neurology* 78:1150–1156, 2012.
- Dogan M, Acikgoz E, Acikgoz M, et al: The frequency of hashimoto thyroiditis in children and the relationship between urinary iodine level and hashimoto thyroiditis, *J Pediatr Endocrinol Metab* 24:75–80, 2011.
- Erol I, Saygi S, Alehan F: Hashimoto's encephalopathy in children and adolescents, *Pediatr Neurol* 45:420–422, 2011.
- Gelfand AA, Gelfand JM, Prabhakar P, et al: Ophthalmoplegic “migraine” or recurrent ophthalmoplegic cranial neuropathy: new cases and a systematic review, *J Child Neurol* 27:759–766, 2012.
- Graus F, Titulaer MJ, Balu R, et al: A clinical approach to diagnosis of autoimmune encephalitis, *Lancet Neurol* 15:391–404, 2016.
- Haberlandt E, Bast T, Ebner A, et al: Limbic encephalitis in children and adolescents, *Arch Dis Child* 96:186–191, 2011.
- Hacohen Y, Absoud M, Deiva K, et al: Myelin oligodendrocyte glycoprotein antibodies are associated with a non-MS course in children, *Neurol Neuroimmunol Neuroinflamm* 2:e81, 2015.
- Heine J, Pruss H, Bartsch T, et al: Imaging of autoimmune encephalitis—relevance for clinical practice and hippocampal function, *Neurosci* 309:68–83, 2015.
- Honnorat J, Didelot A, Karantoni E, et al: Autoimmune limbic encephalopathy and anti-hu antibodies in children without cancer, *Neurology* 80:2226–2232, 2013.
- Irani SR, Michell AW, Lang B, et al: Faciobrachial dystonic seizures precede lg1 antibody limbic encephalitis, *Ann Neurol* 69:892–900, 2011.
- Ize-Ludlow D, Gray JA, Sperling MA, et al: Rapid-onset obesity with hypothalamic dysfunction, hypoventilation, and autonomic dysregulation presenting in childhood, *Pediatrics* 120:e179–e188, 2007.
- Kelley BP, Patel SC, Marin HL, et al: Autoimmune encephalitis: pathophysiology and imaging review of an overlooked diagnosis, *AJNR Am J Neuroradiol* 38(6):1070–1078, 2017.
- Krupp LB, Tardieu M, Amato MP, et al: International pediatric multiple sclerosis study group criteria for pediatric multiple sclerosis and immune-mediated central nervous system demyelinating disorders: revisions to the 2007 definitions, *Mult Scler* 19:1261–1267, 2013.
- Lagarde S, Villeneuve N, Trébuchon A, et al: Anti-tumor necrosis factor alpha therapy (adalimumab) in Rasmussen's encephalitis: an open pilot study, *Epilepsia* 57:956–966, 2016.
- Lancaster E, Martinez-Hernandez E, Titulaer MJ, et al: Antibodies to metabotropic glutamate receptor 5 in the ophelia syndrome, *Neurology* 77:1698–1701, 2011.
- Laurent C, Capron J, Quillerou B, et al: Steroid-responsive encephalopathy associated with autoimmune thyroiditis (STREAT): characteristics, treatment and outcome in 251 cases from the literature, *Autoimmun Rev* 15:1129–1133, 2016.
- Lilleker JB, Jones MS, Mohanraj R, et al: The relevance of VGKC positivity in the absence of LGI1 and caspr2 antibodies, *Neurology* 87:1848–1849, 2016.
- Lim M, Hachohen Y, Vincent A: Autoimmune encephalitis, *Pediatr Clin North Am* 62:667–685, 2015.
- Longoni G, Levy DM, Yeh EA: The changing landscape of childhood inflammatory central nervous system disorders, *J Pediatr* 179:24–32, 2016.
- McKeon A, Martinez-Hernandez E, Lancaster E, et al: Glycine receptor autoimmune spectrum with stiff-man syndrome phenotype, *JAMA Neurol* 70:44–50, 2013.
- Mitchell WG, Wooten AA, O'Neil SH, et al: Effect of increased immunosuppression on developmental outcome of opsoclonus myoclonus syndrome (OMS), *J Child Neurol* 30:976–982, 2015.
- Nandi-Munshi D, Taplin CE: Thyroid-related neurological disorders and complications in children, *Pediatr Neurol* 52:373–382, 2015.
- Odaka M, Yuki N, Yamada M, et al: Bickerstaff's brainstem encephalitis: clinical features of 62 cases and a subgroup associated with Guillain-barré syndrome, *Brain* 126:2279–2290, 2003.
- Petit-pedrol M, Armangue T, Peng X, et al: Encephalitis with refractory seizures, status epilepticus, and antibodies to the GABA A receptor: a case series, characterisation of the antigen, and analysis of the effects of antibodies, *Lancet Neurol* 13:276–286, 2014.
- Pittock SJ, Debruyne J, Krecke KN, et al: Chronic lymphocytic inflammation with pontine perivascular enhancement responsive to steroids (CLIPPERS), *Brain* 133:2626–2634, 2010.
- Planaguma J, Leyboldt F, Mannara F, et al: Human N-methyl d-aspartate receptor antibodies alter memory and behaviour in mice, *Brain* 138:94–109, 2015.
- Pranzatelli MR, Tate ED, Verhulst SJ, et al: Pediatric dosing of rituximab revisited: serum concentrations in opsoclonus-myoclonus syndrome, *J Pediatr Hematol Oncol* 32:e167–e172, 2010.
- Saiz A, Blanco Y, Sabater L, et al: Spectrum of neurological syndromes associated with glutamic acid decarboxylase antibodies: diagnostic clues for this association, *Brain* 131:2553–2563, 2008.
- Schmitt SE, Pargeon K, Frechette ES, et al: “Extreme delta brush”: a unique EEG pattern in adults with anti-NMDA receptor encephalitis, *Neurology* 79:1094–1100, 2012.
- Schubert D, Bode C, Kenefick R, et al: Autosomal dominant immune dysregulation syndrome in humans with CTLA4 mutations, *Nat Med* 20:1410–1416, 2014.
- Singh RR, Sedani S, Lim M, et al: RANBP2 mutation and acute necrotizing encephalopathy: 2 cases and a literature review of the expanding clinico-radiological phenotype, *Eur J Paediatr Neurol* 19:106–113, 2015.
- Spatola M, Petit-Pedrol M, Simabukuro MM, et al: Investigations in GABAA receptor antibody-associated encephalitis, *Neurology* 88(11):1012–1020, 2017.
- Symmonds M, Waters PJ, Küker W, et al: Anti-MOG antibodies with longitudinally extensive transverse myelitis preceded by CLIPPERS, *Neurology* 84:1177–1179, 2015.
- Titulaer MJ, Höftberger R, Iizuka T, et al: Overlapping demyelinating syndromes and anti-N-methyl-d-aspartate receptor encephalitis, *Ann Neurol* 75:411–428, 2014.
- Titulaer MJ, McCracken L, Gabilondo I, et al: Treatment and prognostic factors for long-term outcome in patients with anti-NMDA receptor encephalitis: an observational cohort study, *Lancet Neurol* 12:157–165, 2013.
- Van BA, Stephani U, Kluger G, et al: FIRES: febrile infection responsive epileptic (FIRE) encephalopathies of school age, *Brain Dev* 31:91–93, 2009.
- Van Sonderen A, Petit-Pedrol M, Dalmau J, Titulaer MJ: The value of LGI1, Caspr2, and voltage-gated potassium channel (VGKC) antibodies in encephalitis, *Nat Rev Neurol* 13(5):290–301, 2017.
- Wingerchuk DM, Banwell B, Bennett JL, et al: International consensus diagnostic criteria for neuromyelitis optica spectrum disorders, *Neurology* 85:177–189, 2015.
- Zhou JY, Xu B, Lopes J, et al: Hashimoto encephalopathy: literature review, *Acta Neurol Scand* 135:285–290, 2017.

Chapter 188

Hereditary Periodic Fever Syndromes and Other Systemic Autoinflammatory Diseases

James W. Verbsky

The hereditary periodic fever syndromes are a group of monogenic diseases that present with recurrent bouts of fever and associated pleural and/or peritoneal inflammation, arthritis, and various types of skin rash. A number of identifiable disorders present with recurrent episodes of inflammation, although fevers may not be common feature. Therefore the term **systemic autoinflammatory diseases** is used to include all diseases that present with seemingly unprovoked episodes of inflammation, without the high-titer autoantibodies or antigen-specific T cells typically seen in autoimmune diseases. Whereas the autoimmune diseases are disorders of the *adaptive* immune system, driven by B and T lymphocyte effector cells, autoinflammatory diseases largely represent disorders of the phylogenetically more primitive *innate* immune system, mediated by myeloid effector cells and germline-encoded receptors. Autoinflammatory diseases exhibit episodic or persistent inflammation characterized by an acute-phase response with elevation of the erythrocyte sedimentation rate (ESR), C-reactive protein (CRP), and serum amyloid A (AA). In some patients, untreated autoinflammatory disorders over time will lead to AA amyloidosis (see Chapter 189).

It is important to note that autoinflammatory disorders are rare, whereas fever in childhood caused by innocuous illness is very common. The approach to a child with fevers should include a detailed history, physical examination, and limited laboratory investigations to rule out other conditions that lead to fevers, including autoimmune disorders and malignancies (Table 188.1). If there is evidence of recurrent infections with fevers, an immune deficiency could be considered and evaluated. If the workup is reassuring, the inflammatory episodes resolve, and the child is otherwise well without unusual physical findings, observance is often warranted because these episodes are likely to resolve as the child's immune system matures.

CLASSIFICATION OF AUTOINFLAMMATORY DISORDERS

Because of the rapidly expanding number of autoinflammatory disorders and their varied clinical presentation, it can be difficult to group these disorders in a meaningful manner. Some autoinflammatory disorders present with prominent fevers and are known as **hereditary periodic fever syndromes**. These include 2 disorders with an *autosomal recessive* mode of inheritance, familial Mediterranean fever (FMF; MIM249100) and the hyperimmunoglobulinemia D (hyper-IgD) with periodic fever syndrome (HIDS; MIM260920). Hereditary periodic fever syndromes with an *autosomal dominant* mode of inheritance include the tumor necrosis factor (TNF) receptor-associated periodic syndrome (TRAPS; MIM191190) and a spectrum of disorders known as the cryopyrin-associated periodic syndromes (CAPS), or cryopyrinopathies. From mildest to most severe, CAPS include the familial cold autoinflammatory syndrome (FCAS1; MIM120100), Muckle-Wells syndrome (MWS; MIM191100), and neonatal-onset multisystem inflammatory disease (NOMID; MIM607115) (also known as chronic infantile neurologic cutaneous and articular syndrome, CINCA) (Table 188.2).

A variety of mendelian *autoinflammatory disorders* may or may not exhibit prominent fevers and are not considered periodic fever syndromes,

Keywords

fever syndrome
autoinflammatory
TNF- α
IL-1 β
interferons
inflammation
genetic disorder
familial Mediterranean fever
FMF
hyper-IgD with periodic fever syndrome
HIDS
TNF receptor-associated periodic syndrome
TRAPS
cryopyrin-associated periodic syndromes
CAPS
chronic infantile neurologic cutaneous and articular syndrome
CINCA
Muckle-Wells syndrome
familial cold autoinflammatory syndrome
FCAS
syndrome of pyogenic arthritis with pyoderma gangrenosum and
acne
PAPA
deficiency of IL-1 receptor antagonist
DIRA
Blau syndrome
autoinflammation with phospholipase C γ_2 -associated antibody
deficiency and immune dysregulation
APLAID
deficiency of adenosine deaminase-2
DADA2
deficiency in IL-36 receptor antagonist
DITRA
interferonopathies

Table 188.1 Differential Diagnosis of Periodic Fever**HEREDITARY**

See Table 188.2.

NONHEREDITARY**A. Infectious**

1. Hidden infectious focus (e.g., aortoenteric fistula, lung sequestration)
2. Recurrent infection/reinfection (e.g., chronic meningococcemia, immune deficiency)
3. Specific infection (e.g., Whipple disease, malaria)

B. Noninfectious inflammatory disorder:

1. Adult-onset Still disease
2. Systemic-onset juvenile idiopathic arthritis
3. Periodic fever, aphthous stomatitis, pharyngitis, and adenitis
4. Schnitzler syndrome
5. Behçet syndrome
6. Crohn disease
7. Sarcoidosis

C. Neoplastic

1. Lymphoma (e.g., Hodgkin disease, angioimmunoblastic lymphoma)
2. Solid tumor (e.g., pheochromocytoma, myxoma, colon carcinoma)
3. Histiocytic disorders

D. Vascular (e.g., recurrent pulmonary embolism)**E. Hypothalamic****F. Psychogenic periodic fever****G. Factitious or fraudulent**

Adapted from Simon A, van der Meer JWM, Drenth JPH: Familial autoinflammatory syndromes. In Firestein GS, Budd RC, Gabriel SE, et al, editors: *Kelley's textbook of rheumatology*, ed 9, Philadelphia, 2012, Saunders (Table 97-2).

but do have continuous or repeated episodes of spontaneous inflammation with unique clinical characteristics. These include the syndrome of pyogenic arthritis with pyoderma gangrenosum and acne (**PAPA**; MIM604416), deficiency of the interleukin-1 (IL-1) receptor antagonist (**DIRA**; MIM612852), **Blau syndrome** caused by mutations in *NOD2* (also known as *early-onset sarcoidosis*; MIM186580), autoinflammation with phospholipase C γ -associated antibody deficiency and immune dysregulation (**APLAID**; MIM614878), and deficiency of adenosine deaminase-2 (**DADA2**). Other disorders include congenital sideroblastic anemia with B-cell immunodeficiency, periodic fevers, and developmental delay (**SIFD**) caused by biallelic mutations of the *TRNT1* gene (MIM616084), autoinflammation with infantile enterocolitis caused by mutations in *NLRC4* (**AIPEC**; MIM616060), familial cold autoinflammatory syndrome type 2 caused by mutations in *NLRP12* (**FCAS2**; MIM611762), **CARD14** (MIM607211), and deficiency in IL-36 receptor antagonist (**DITRA**; 614204).

In addition to the previous autoinflammatory disorders, a variety of disorders are characterized by inappropriate *interferon expression*, the **interferonopathies**. Type 1 interferons (e.g., IFN- α , IFN- β) are cytokines expressed by many cells in response to viral infections. Disorders that result in spontaneous interferon production and inflammatory manifestations include STING-associated vasculopathy of infancy (**SAVI**; MIM615934) and chronic atypical neutrophilic dermatosis with lipodystrophy and elevated temperature (**CANDLE**; MIM256040).

There are also a number of autoinflammatory disorders with a complex mode of inheritance. These include the syndrome of periodic fever with aphthous stomatitis, pharyngitis, and adenitis (**PFAPA**) and chronic recurrent multifocal osteomyelitis (**CRMO**; MIM259680). Other genetically complex disorders that are sometimes considered autoinflammatory include **systemic-onset juvenile idiopathic arthritis** (see Chapter 180), **Behçet disease** (see Chapter 186), and **Crohn disease** (see Chapter 362.2).

Distinguishing autoinflammatory disorders from one another can be difficult because their presentations can vary, and many display similarities. Some disorders have characteristic fever patterns (Fig. 188.1), whereas others have characteristic skin findings that can aid in a diagnosis

(Table 188.3). Others can have characteristic physical features or organ involvement. Some of these disorders have bone involvement (Table 188.4). Other clinical features can also be helpful, such as ethnicity, age of onset, triggers, laboratory testing, and response to therapies (Table 188.5). Genetic panels are increasingly being used to screen for most if not all of these defects in a single test, rather than individual genetic assessment based on clinical findings.

AUTOINFLAMMATORY DISEASES WITH PERIODIC OR PROMINENT FEVERS

The first descriptions of autoinflammatory disorders focused on genetic diseases that presented with prominent fevers, the periodic fever syndromes. As new autoinflammatory diseases were discovered, it was clear that a variety of inflammatory disorders can occur in the absence of fever.

Familial Mediterranean Fever

FMF is a recessively inherited autoinflammatory disease usually characterized by recurrent, short-lived (1-3 days), self-limited episodes of fever, serositis, mono- or pauciarticular arthritis, or an erysipeloid rash, sometimes complicated by AA amyloidosis. Most patients with FMF present with symptoms in childhood, with 90% presenting before age 20. Clinical features of FMF may include fever, serositis presenting as pleuritic chest pain or severe abdominal pain, arthritis, and rash. The pleural pain is typically unilateral, whereas the abdominal pain (sterile peritonitis) can be generalized or localized to 1 quadrant, similar to other forms of peritonitis. FMF-associated arthritis occurs primarily in the large joints, may be accompanied by large, neutrophil-rich effusions, and is usually nonerosive and nondestructive. The hallmark cutaneous finding is an erysipeloid erythematous rash that overlies the ankle or dorsum of the foot (Fig. 188.2). Other clinical findings include scrotal pain caused by inflammation of the tunica vaginalis testis, febrile myalgia, exercise-induced myalgia (particularly common in children), and an association with various forms of vasculitis, including Henoch-Schönlein purpura, in as many as 5% of pediatric patients. FMF episodes may be triggered by stress, menses, or infections. Between flares, patients are generally symptom free but may have persistent elevation of their inflammatory markers. The attack frequency can vary from weekly to 1-2 flares per year. Table 188.6 lists diagnostic criteria for FMF.

FMF is caused by autosomal recessive mutations in *MEFV*, a gene encoding a 781 amino acid protein denoted *pyrin* (Greek for “fever”). Pyrin is expressed in granulocytes, monocytes, and dendritic cells (DCs) and in peritoneal, synovial, and dermal fibroblasts. The N-terminal approximately 90 amino acids of pyrin are the prototype for a motif (the PYRIN domain) that mediates protein-protein interactions and is found in >20 different human proteins that regulate inflammation and apoptosis. Many of the FMF-associated mutations in pyrin are found at the C-terminal B30.2 domain of pyrin, encoded by exon 10 of *MEFV*. More than 50 such FMF mutations are listed in an online database (<http://fmf.igh.cnrs.fr/ISSAID/infervers/>), almost all of which are missense substitutions. Homozygosity for the M694V mutation may be associated with an earlier age of onset, arthritis, and an increased risk of amyloidosis. The substitution of glutamine for glutamic acid at residue 148 (E148Q) is considered either a mild mutation or a functional polymorphism in the pyrin protein. The carrier frequency of FMF mutations among several Mediterranean populations is very high, suggesting the possibility of a heterozygote advantage.

FMF occurs primarily among ethnic groups of Mediterranean ancestry, most frequently Jews, Turks, Armenians, Arabs, and Italians. Because of a higher frequency of the M694V mutation, FMF is more severe and more readily recognized in the Sephardic (North African) than the Ashkenazi (East European) Jewish population. With the advent of genetic testing, mutation-positive FMF has been documented worldwide, although at lower frequency than in the Mediterranean basin and Middle East.

Through PYRIN-domain interactions, pyrin can activate **caspase-1**, the enzyme that converts the 31 kDa pro-IL-1 β molecule into the biologically active 17 kDa IL-1 β , which is a major mediator of fever and inflammation. FMF mutations lead to a gain-of-function activation

Table 188.2 Autoinflammatory Disorders

DISEASE	GENETIC DEFECT/PRESUMED PATHOGENESIS	INHERITANCE	AFFECTED CELLS	FUNCTIONAL DEFECTS	ASSOCIATED FEATURES
Familial Mediterranean fever	Mutations of <i>MEFV</i> (lead to gain of pyrin function, resulting in inappropriate IL-1 β release)	AR	Mature granulocytes, cytokine-activated monocytes	Decreased production of pyrin permits ASC-induced IL-1 processing and inflammation following subclinical serosal injury; macrophage apoptosis decreased	Recurrent fever, serositis, and inflammation responsive to colchicine. Predisposes to vasculitis and inflammatory bowel disease
Mevalonate kinase deficiency (hyper IgD syndrome)	Mutations of <i>MVK</i> (lead to a block in the mevalonate pathway). Interleukin-1 β mediates the inflammatory phenotype	AR		Affecting cholesterol synthesis; pathogenesis of disease is unclear	Periodic fever and leukocytosis with high IgD levels
Muckle-Wells syndrome	Mutations of <i>NLRP3</i> (also called <i>PYPAF1</i> or <i>NALP3</i>) lead to constitutive activation of the <i>NLRP3</i> inflammasome	AD	PMNs, monocytes	Defect in cryopyrin, involved in leukocyte apoptosis and NF- κ B signaling and IL-1 processing	Urticaria, SNHL, amyloidosis
Familial cold autoinflammatory syndrome	Mutations of <i>NLRP3</i> (see above) Mutations of <i>NLRP12</i>	AD	PMNs, monocytes	Same as above	Nonpruritic urticaria, arthritis, chills, fever, and leukocytosis after cold exposure
Neonatal-onset multisystem inflammatory disease (NOMID) or chronic infantile neurologic cutaneous and articular syndrome (CINCA)	Mutations of <i>NLRP3</i> (see above)		PMNs, chondrocytes	Same as above	Neonatal-onset rash, chronic meningitis, and arthropathy with fever and inflammation
TNF receptor-associated periodic syndrome (TRAPS)	Mutations of <i>TNFRSF1A</i> (resulting in increased TNF-inflammatory signaling)	AD	PMNs, monocytes	Mutations of 55-kDa TNF receptor leading to intracellular receptor retention or diminished soluble cytokine receptor available to bind TNF	Recurrent fever, serositis, rash, and ocular or joint inflammation
Pyogenic sterile arthritis, pyoderma gangrenosum, acne (PAPA) syndrome	Mutations of <i>PSTPIP1</i> (also called <i>C2BP1</i>) (affects both pyrin and protein tyrosine phosphatase to regulate innate and adaptive immune responses)	AD	Hematopoietic tissues, upregulated in activated T cells	Disordered actin reorganization leading to compromised physiologic signaling during inflammatory response	Destructive arthritis, inflammatory skin rash, myositis
Blau syndrome	Mutations of <i>NOD2</i> (also called <i>CARD15</i>) (involved in various inflammatory processes)	AD	Monocytes	Mutations in nucleotide binding site of <i>CARD15</i> , possibly disrupting interactions with lipopolysaccharides and NF- κ B signaling	Uveitis, granulomatous synovitis, campodactyly, rash, and cranial neuropathies, 30% develop Crohn disease
Chronic recurrent multifocal osteomyelitis and congenital dyserythropoietic anemia (Majeed syndrome)	Mutations of <i>LPIN2</i> (increased expression of the proinflammatory genes)	AR	Neutrophils, bone marrow cells	Undefined	Chronic recurrent multifocal osteomyelitis, transfusion-dependent anemia, cutaneous inflammatory disorders
Early-onset inflammatory bowel disease	Mutations in <i>IL-10</i> (results in increase of many proinflammatory cytokines)	AR	Monocyte/macrophage, activated T cells	IL-10 deficiency leads to increase of TNF γ and other proinflammatory cytokines	Enterocolitis, enteric fistulas, perianal abscesses, chronic folliculitis
Early-onset inflammatory bowel disease	Mutations in <i>IL-10RA</i> (see above)	AR	Monocyte/macrophage, activated T cells	Mutation in IL-10 receptor alpha leads to increase of TNF γ and other proinflammatory cytokines	Enterocolitis, enteric fistulas, perianal abscesses, chronic folliculitis
Early-onset inflammatory bowel disease	Mutations in <i>IL-10RB</i> (see above)	AR	Monocyte/macrophage, activated T cells	Mutation in IL-10 receptor beta leads to increase of TNF γ and other proinflammatory cytokines	Enterocolitis, enteric fistulas, perianal abscesses, chronic folliculitis

AD, autosomal dominant; AR, autosomal recessive; Ig, immunoglobulin; IL, interleukin; NF- κ B, nuclear factor- κ B; PMN, polymorphonuclear neutrophil; SNHL, sensorineural hearing loss; TNF, tumor necrosis factor. From Verbsky JW, Routes JR: Recurrent fever, infections, immune disorders, and autoinflammatory diseases. In Kliegman RM, Lyse PS, Bordini BJ, et al, editors: Nelson pediatric symptom-based diagnosis. Philadelphia, 2018, Elsevier, Table 41-5.

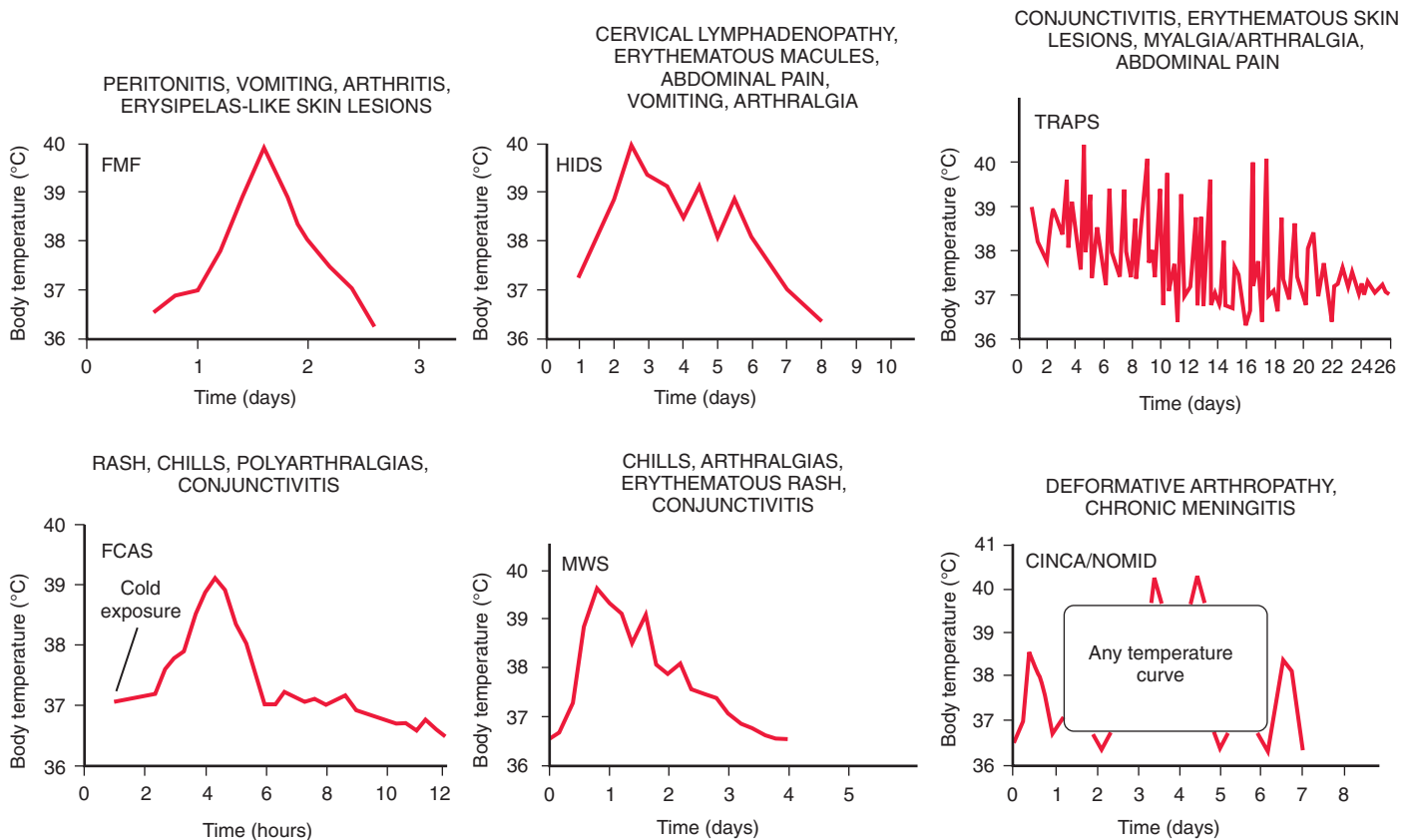


Fig. 188.1 Characteristic patterns of body temperature during inflammatory attacks in the familial autoinflammatory syndromes. Interindividual variability for each syndrome is considerable, and even for the individual patient, the fever pattern may vary greatly from episode to episode. Note the different time scales on the x axes. CINCA/NOMID, Chronic infantile neurologic cutaneous and articular syndrome/neonatal-onset multisystemic inflammatory disease; FCAS, familial cold autoinflammatory syndrome; HIDS, hyper-IgD syndrome; MWS, Muckle-Wells syndrome; TRAPS, tumor necrosis factor receptor-associated periodic syndrome. (From Simon A, van der Meer JWM, Drenth JPH: *Familial autoinflammatory syndromes*. In Firestein GS, Budd RC, Gabriel SE, et al, editors: *Kelley’s textbook of rheumatology*, ed 9, Philadelphia, 2012, Saunders, Fig 97-1.)

Table 188.3 Clinical Grouping of Autoinflammatory Diseases by Skin Manifestations	
<ol style="list-style-type: none"> Neutrophilic urticaria (the cryopyrinopathies) <ul style="list-style-type: none"> Recurrent fever attacks of short duration (typically <24 hr) <ul style="list-style-type: none"> CAPS/FCAS: familial cold autoinflammatory syndrome CAPS/MWS: Muckle-Wells syndrome FCAS2/NLRP12 Continuous low-grade fever <ul style="list-style-type: none"> CAPS/NOMID: neonatal-onset multisystem inflammatory disease (NOMID)/chronic infantile neurologic cutaneous and articular syndrome (CINCA) Granulomatous skin lesions and minimal or low-grade fever attacks <ul style="list-style-type: none"> Blau syndrome/early-onset sarcoidosis (pediatric granulomatous arthritis) Pustular skin rashes and fever <ul style="list-style-type: none"> With inflammatory bone disease <ul style="list-style-type: none"> DIRA: deficiency of interleukin-1 receptor agonist Majeed syndrome 	<ul style="list-style-type: none"> With pyogenic arthritis <ul style="list-style-type: none"> PAPA: pyogenic arthritis, pyoderma gangrenosum, and acne syndrome Without other organ involvement <ul style="list-style-type: none"> DITRA: deficiency of interleukin-36 receptor antagonist CAMPS: CARD14-mediated psoriasis <ol style="list-style-type: none"> Atypical neutrophilic dermatosis with histiocytic-like infiltrate <ul style="list-style-type: none"> CANDLE: proteasome associated autoinflammatory syndromes Livedo reticularis, vasculopathy with ulcerations <ul style="list-style-type: none"> SAVI; STING associated vasculopathy, infantile onset Livedo racemosa, vasculitis with ulcerations <ul style="list-style-type: none"> ADA2; adenosine deaminase-2 deficiency

CAPS, Cryopyrin-associated periodic syndromes. Modified from Almeida de Jesus A, Goldbach-Mansky R: Monogenic autoinflammatory diseases: concept and clinical manifestations, *Clin Immunol* 147:155–174, 2013 (Table 1).

of caspase-1 and IL-1β-dependent inflammation, with a gene-dosage effect. These results may explain why as many as 30% of heterozygous carriers of FMF mutations have biochemical evidence of inflammation. Prophylactic daily oral colchicine decreases the frequency, duration, and intensity of FMF flares. This regimen also prevents the development of systemic AA amyloidosis. Colchicine is generally well tolerated and

safe in children, with the most common side effects being diarrhea and other gastrointestinal (GI) complaints. Some patients develop lactose intolerance while taking colchicine. GI side effects can be minimized by initiating therapy at a low dose (for young children, 0.3 mg/day) and slowly titrating upward. A dose-related transaminitis may also be observed; bone marrow suppression is rarely seen at the dosages

Table 188.4 Autoinflammatory Bone Disorders					
	CRMO	MAJEED SYNDROME	DIRA	CHERUBISM	CMO AND LUPO MICE
Ethnicity	Worldwide, but mostly European	Arabic	European, Puerto Rican, Arabic	Worldwide	Occurs in various backgrounds
Fever	Uncommon	Common	Uncommon	No	Not assessed
Sites of osseous involvement	Metaphyses of long bones > vertebrae, clavicle, sternum, pelvis, others	Similar to CRMO	Anterior rib ends, metaphyses of long bones, vertebrae, others	Mandible > maxilla Rarely ribs	Vertebrae hind > forefeet
Extrasosseous manifestations	PPP, psoriasis, IBD, others	Dyserythropoietic anemia, Sweet syndrome, HSM, growth failure	Generalized pustulosis, nail changes, lung disease, vasculitis	Cervical lymphadenopathy	Dermatitis, extramedullary hematopoiesis, splenomegaly
Family history of inflammatory disorders	Psoriasis, PPP, arthritis, IBD, others	Psoriasis in some obligate carriers	No known associations	No known associations	Heterozygotes normal
Inheritance	Not clear	Autosomal recessive	Autosomal recessive	Autosomal dominant; incomplete penetrance	Autosomal recessive
Gene defect	Unknown	<i>LPIN2</i>	<i>IL1RN</i>	<i>SH3BP2</i> >> <i>PTPN11</i>	<i>Pstpip2</i>
Protein name	?	Lipin2	IL-1Ra	SH3BP2	PSTPIP2 (MAYP)
Protein function	?	Fat metabolism: (PAP enzyme activity), ↑ message to oxidative stress, ? role in mitosis	Antagonist of IL-1 receptor	↑ Myeloid cell response to M-CSF and RANKL, ↑ TNF-α expression in macrophages	Macrophage proliferation, macrophage recruitment to sites of inflammation, cytoskeletal function
Cytokine abnormalities	↑ serum TNF-α	Not tested	↑ IL-1α, IL-1β, MIP-1α, TNF-α, IL-8, IL-6 ex vivo monocyte assay; skin reveals ↑ IL-17 staining	↑ serum TNF-α in mouse model	cmo: ↑ serum IL-6, MIP-1α, TNF-α, CSF-1, IP-10 Lupo: ↑ serum MIP-1α, IL-4, RANTES, TGF-β

CRMO, Chronic recurrent multifocal osteomyelitis; CSF, colony-stimulating factor; DIRA, deficiency of interleukin-1 receptor antagonist; HSM, hepatosplenomegaly; IBD, inflammatory bowel disease; IL, interleukin; IL-1Ra, interleukin-1 receptor antagonist; IP-10, interferon-inducible protein-10; M-CSF, macrophage colony-stimulating factor; MIP-1α, macrophage inflammatory protein-1α; PAP, phosphatidate phosphatase; PPP, palmar-plantar pustulosis; PSTPIP2, proline-serine-threonine phosphatase interacting protein; RANKL, receptor activator of nuclear factor-κB ligand; RANTES, regulated on activation, normal T cell expressed and secreted; SH3BP2, SH3 binding protein 2; TGF, transforming growth factor; TNF-α, tumor necrosis factor alpha.

From Ferguson PJ, Laxer RM: Autoinflammatory bone disorders. In Cassidy JT, Petty RE, Laxer RM, et al, editors: *Textbook of pediatric rheumatology*, ed 6, Philadelphia, 2010, Saunders (Table 44-2).

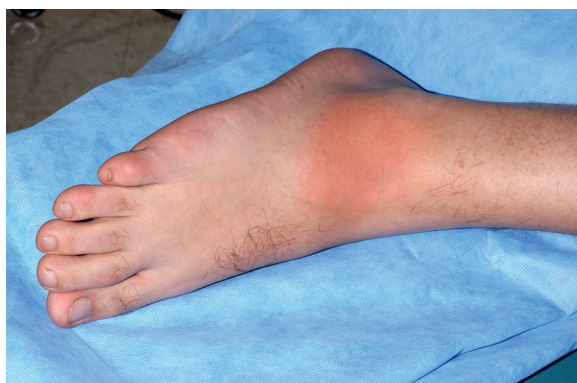

Fig. 188.2 Characteristic erysipeloid erythema associated with familial Mediterranean fever. This rash appears during a flare and overlies the ankle or dorsum of the foot.

prescribed for FMF. Pediatric patients may require doses of colchicine similar to those needed in adults (1–2 mg/day), reflecting that children metabolize the drug more rapidly than adults. It is not always possible to find a tolerated dose of colchicine at which all symptoms are suppressed, but approximately 90% of patients have a marked improvement in disease-related symptoms. A small percentage of FMF patients are

either unresponsive to or intolerant of therapeutic doses of colchicine. Based on the role of pyrin in IL-1β activation, a trial demonstrated the safety and effectiveness of *riloncept*, an IL-1 inhibitor, in FMF; there are case reports of the effectiveness of *anakinra*, a recombinant interleukin-1 receptor (IL-1R) antagonist.

Amyloidosis is the most serious complication of FMF, and in its absence FMF patients may live a normal life span. Amyloidosis may develop when serum AA, an acute-phase reactant found at extremely high levels in the blood during FMF attacks, is cleaved to produce a 76-amino acid fragment that misfolds and deposits ectopically, usually in the kidneys, GI tract, spleen, lungs, testes, thyroid, and adrenals. Rarely, cardiac amyloidosis may develop; macroglossia and amyloid neuropathy are generally not seen with the amyloidosis of FMF. The most common presenting sign of AA amyloidosis is proteinuria. The diagnosis is then usually confirmed by rectal or renal biopsy. In a small number of case reports, mostly from the Middle East, amyloidosis may actually precede overt FMF attacks, presumably because of subclinical inflammation. Risk factors for the development of amyloidosis in FMF include homozygosity for the M694V *MEFV* mutation, polymorphisms of the serum AA gene (encoding AA), noncompliance with colchicine treatment, male gender, and a positive family history of AA amyloid. For unclear reasons, country of origin is also a major risk factor for amyloidosis in FMF, with patients raised in the Middle East having a much higher risk than genotypically identical patients raised in the West. Aggressive lifelong suppression of the acute-phase reactants should be the goal in patients with FMF amyloidosis, and documented cases

Table 188.5 Clues That May Assist in Diagnosis of Autoinflammatory Syndromes

AGE OF ONSET	
At birth	NOMID, DIRA, MWS
Infancy and 1st yr of life	HIDS, FCAS, NLRP12
Toddler	PFAPA
Late childhood	PAPA
Most common of autoinflammatory syndromes to have onset in adulthood	TRAPS, DITRA
Variable (mostly in childhood)	All others
ETHNICITY AND GEOGRAPHY	
Armenians, Turks, Italian, Sephardic Jews	FMF
Arabs	FMF, DITRA (Arab Tunisian)
Dutch, French, German, Western Europe	HIDS, MWS, NLRP12
United States	FCAS
Can occur in blacks (West Africa origin)	TRAPS
Eastern Canada, Puerto Rico	DIRA
Worldwide	All others
TRIGGERS	
Vaccines	HIDS
Cold exposure	FCAS, NLRP12
Stress, menses	FMF, TRAPS, MWS, PAPA, DITRA
Minor trauma	PAPA, MWS, TRAPS, HIDS
Exercise	FMF, TRAPS
Pregnancy	DITRA
Infections	All, especially DITRA
ATTACK DURATION	
<24 hr	FCAS, FMF
1-3 days	FMF, MWS, DITRA (fever)
3-7 days	HIDS, PFAPA
>7 days	TRAPS, PAPA
Almost always "in attack"	NOMID, DIRA
INTERVAL BETWEEN ATTACKS	
3-6 wk	PFAPA, HIDS
>6 wk	TRAPS
Mostly unpredictable	All others
Truly periodic	PFAPA, cyclic neutropenia
USEFUL LABORATORY TESTS	
Acute-phase reactants must be normal between attacks	PFAPA
Urine mevalonic acid in attack	HIDS
IgD > 100 mg/dL	HIDS
Proteinuria (amyloidosis)	FMF, TRAPS, MWS, NOMID
RESPONSE TO THERAPY	
Corticosteroid dramatic	PFAPA
Corticosteroid partial	TRAPS, FCAS, MWS, NOMID, PAPA*
Colchicine	FMF, PFAPA (30% effective)
Cimetidine	PFAPA (30% effective)
Etanercept	TRAPS, FMF arthritis
Anti-IL-1 dramatic	DIRA (anakinra), FCAS, MWS, NOMID, PFAPA
Anti-IL-1 mostly	TRAPS, FMF
Anti-IL-1 partial	HIDS, PAPA

DIRA, Deficiency of IL-1 receptor antagonist; DITRA, deficiency of IL-36 receptor antagonist (generalized pustular psoriasis); FCAS, familial cold autoinflammatory syndrome; FMF, familial Mediterranean fever; HIDS, hyper-IgD syndrome; IL, interleukin; MWS, Muckle-Wells syndrome; NLRP, nucleotide oligomerization domain-like receptor family, pyrin domain; NOMID, neonatal-onset multisystem inflammatory disorder; PAPA, pyogenic sterile arthritis, pyoderma gangrenosum, acne syndrome; PFAPA, periodic fever, aphthous stomatitis, pharyngitis, adenitis; TRAPS, tumor necrosis factor receptor-associated periodic syndrome.
 *For intraarticular corticosteroids.
 From Hashkes PJ, Tokar O: Autoinflammatory syndromes, *Pediatr Clin North Am* 59:447-470, 2012 (Table 2).

Table 188.6 Diagnostic Criteria for Familial Mediterranean Fever (FMF)*

MAJOR CRITERIA
1. Typical attacks [†] with peritonitis (generalized)
2. Typical attacks with pleuritis (unilateral) or pericarditis
3. Typical attacks with monoarthritis (hip, knee, ankle)
4. Typical attacks with fever alone
5. Incomplete abdominal attack
MINOR CRITERIA
1. Incomplete attacks [‡] involving chest pain
2. Incomplete attacks involving monoarthritis
3. Exertional leg pain
4. Favorable response to colchicine

*Requirements for diagnosis of FMF are ≥1 major criteria or ≥2 minor criteria.
[†]Typical attacks are defined as recurrent (≥3 of the same type), febrile (≥38°C), and short (lasting between 12 hr and 3 days).
[‡]Incomplete attacks are defined as painful and recurrent attacks not fulfilling the criteria for a typical attack.
 From Livneh A, Langevitz P, Zemer D, et al: Criteria for the diagnosis of familial Mediterranean fever, *Arthritis Rheum* 40:1879-1885, 1997.

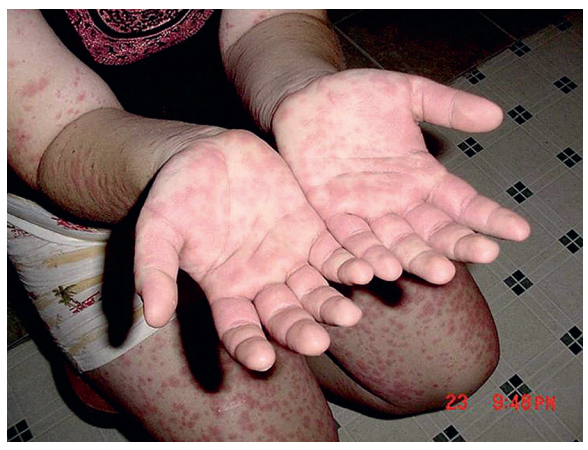

Fig. 188.3 Polymorphic rash on the hands, arms, and legs of a patient with hyper-IgD syndrome (HIDS). (From Takada K, Aksentijevich I, Mahadevan V, et al. Favorable preliminary experience with etanercept in two patients with the hyperimmunoglobulinemia D and periodic fever syndrome, *Arthritis Rheum* 48:2646, 2003.)

show this may result in resorption of amyloid deposits. The natural history of untreated amyloidosis in FMF is the inexorable progression to renal failure, often within 3-5 yr.

Hyperimmunoglobulinemia D With Periodic Fever Syndrome

HIDS, also known as **mevalonate kinase deficiency**, was initially described in a cohort of Dutch patients and occurs primarily in patients of Northern European descent. HIDS is recessively inherited and caused by mutations of *MVK*, a gene that encodes mevalonate kinase (MK). The clinical features of HIDS generally appear within the 1st 6 mo of life. Febrile attacks last 3-7 days, with abdominal pain often accompanied by diarrhea, nausea, and vomiting. Other clinical manifestations include cervical lymphadenopathy, diffuse macular rash, aphthous ulcers, headaches, and occasional splenomegaly (Figs. 188.3 to 188.5). Arthritis or arthralgia can be present in an oligoarticular or polyarticular pattern. Inflammatory disease-like illness and Kawasaki disease-like presentation have also been reported. Attacks are often precipitated by recurrent illness, immunizations, and surgery. Families frequently report flares around the time of birthdays, holidays, and family vacations. The symptoms of HIDS may persist for years but tend to become less prominent in adulthood. Patients with HIDS usually have a normal life

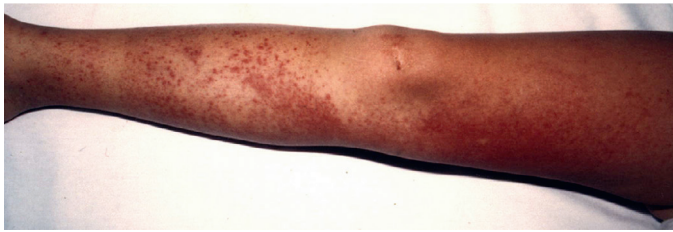

Fig. 188.4 Petechiae on the leg of a hyper-IgD syndrome patient during a febrile attack. (From Simon A, van der Meer JWM, Drenth JPH: *Familial autoinflammatory syndromes*. In Firestein GS, Budd RC, Gabriel SE, et al, editors: *Kelley's textbook of rheumatology*, ed 9, Philadelphia, 2012, Saunders, Fig 97-7.)

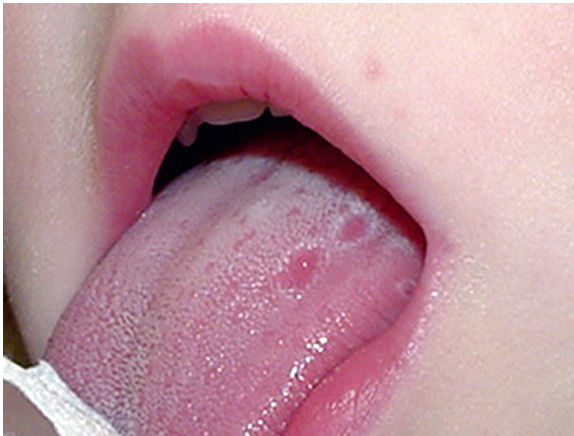

Fig. 188.5 Aphthous ulceration detected on the tongue of a patient with hyper-IgD syndrome. (Courtesy Dr. K. Antila, North Carelian Central Hospital, Joensuu, Finland; from Simon A, van der Meer JWM, Drenth JPH: *Familial autoinflammatory syndromes*. In Firestein GS, Budd RC, Gabriel SE, et al, editors: *Kelley's textbook of rheumatology*, ed 9, Philadelphia, 2012, Saunders, Fig 97-8.)

span. Unlike FMF and TRAPS, the incidence of AA amyloidosis is quite low. Complete MK deficiency results in mevalonic aciduria that presents with severe mental retardation, ataxia, myopathy, cataracts, and failure to thrive (see Chapter 103).

MK is expressed in multiple tissues and catalyzes the conversion of mevalonic acid to 5-phosphomevalonic acid in the biosynthesis of cholesterol and nonsterol isoprenoids. Patients with HIDS-associated mutations have greatly reduced, but not absent, MK enzymatic activity. HIDS patients usually have low-normal serum cholesterol levels, but the deficiency of isoprenoids may cause increased IL-1 β production by aberrant activation of the small guanosine triphosphatase Rac1. Temperature elevation may further exacerbate this process by more complete inhibition of MK activity, leading to a possible positive feedback loop.

The diagnosis of HIDS may be confirmed either by 2 mutations in *MVK* (approximately 10% of patients with seemingly typical disease have only a single identifiable mutation) or by elevated levels of mevalonate in the urine during acute attacks. HIDS-associated mutations are distributed throughout the MK protein, but the 2 most common mutations are the substitution of isoleucine for valine at residue 377 (V377I), a variant that is quite common in the Dutch population, and the substitution of threonine for isoleucine at residue 268 (I268T). The eponymous elevation in serum IgD levels is not universally present, especially in young children; IgA levels can also be elevated. Conversely, serum IgD levels may be increased in other autoinflammatory disorders as well as in some chronic infections. During attacks, leukocytosis and increased serum levels of acute-phase reactants and proinflammatory cytokines are frequently present. [Table 188.7](#) lists diagnostic criteria for HIDS.

Table 188.7 Diagnostic Indicators of Hyper-IgD Syndrome

AT TIME OF ATTACKS

1. Elevated erythrocyte sedimentation rate and leukocytosis
2. Abrupt onset of fever ($\geq 38.5^{\circ}\text{C}$)
3. Recurrent attacks
4. Lymphadenopathy (especially cervical)
5. Abdominal distress (e.g., vomiting, diarrhea, pain)
6. Skin manifestations (e.g., erythematous macules and papules)
7. Arthralgias and arthritis
8. Splenomegaly

CONSTANTLY PRESENT

1. Elevated IgD (above upper limit of normal) measured on 2 occasions at least 1 mo apart*
2. Elevated IgA (≥ 2.6 g/L)

SPECIFIC FEATURES

1. Mutations in mevalonate kinase gene
2. Decreased mevalonate kinase enzyme activity

*Extremely high serum concentrations of IgD are characteristic but not obligatory.

From Firestein GS, Budd RC, Gabriel SE, et al, editors: *Kelley & Firestein's textbook of rheumatology*, ed 10, Philadelphia, 2016, Elsevier (Table 97-4, p 1674).

Standards for the **treatment** of HIDS are evolving. Very few patients respond to colchicine, and milder disease courses may respond to nonsteroidal antiinflammatory drugs (NSAIDs). Corticosteroids are of limited utility. Small trials of both etanercept and either intermittent or daily anakinra in HIDS are promising.

Tumor Necrosis Factor Receptor–Associated Periodic Syndrome

TRAPS is characterized by recurrent fevers and localized inflammation and is inherited in an autosomal dominant manner. TRAPS has a number of distinguishing clinical and immunologic features. TRAPS was first recognized in patients of Irish descent and denoted *familial Hibernian fever* to draw a contrast with FMF, but the current nomenclature was proposed when mutations in *TNFRSF1A* were discovered not only in the original Irish family, but in families from a number of other ethnic backgrounds. *TNFRSF1A* encodes the 55 kDa receptor (denoted p55, TNFR1, or CD120a) for TNF- α that is widely expressed on a number of cell types. A 2nd 75 kDa receptor is largely restricted to leukocytes.

Patients with TRAPS typically present within the 1st decade of life with flares that occur with variable frequency but of often substantially longer duration than FMF or HIDS flares. The febrile episodes of TRAPS last at least 3 days and can persist for weeks. There may be pleural and peritoneal involvement. At times, patients present with signs of an acute abdomen; on exploration such patients have *sterile peritonitis*, sometimes with adhesions from previous episodes. Patients may also have nausea and frequently report constipation at the onset of flares that progresses to diarrhea by the conclusion. Ocular signs include periorbital edema and conjunctivitis. TRAPS patients may also experience severe myalgia and on imaging, the muscle groups may have focal areas of edema. Many rashes can be seen in TRAPS patients, but the most common is an erythematous macular rash that on biopsy contains superficial and deep perivascular infiltrates of mononuclear cells. Patients often report that the rash migrates distally on a limb during its course with an underlying myalgia and can resemble cellulitis. Other rashes include erythematous annular patches as well as a serpiginous rash ([Fig. 188.6](#)). Approximately 10–15% of patients with TRAPS may develop AA amyloidosis; the presence of cysteine mutations and a positive family history are risk factors for this complication. If amyloidosis does not develop, TRAPS patients have a normal life expectancy. [Table 188.8](#) lists diagnostic criteria.

Almost all the TRAPS-associated mutations are in the extracellular domain of the TNFR1 protein, with about one-third involving the

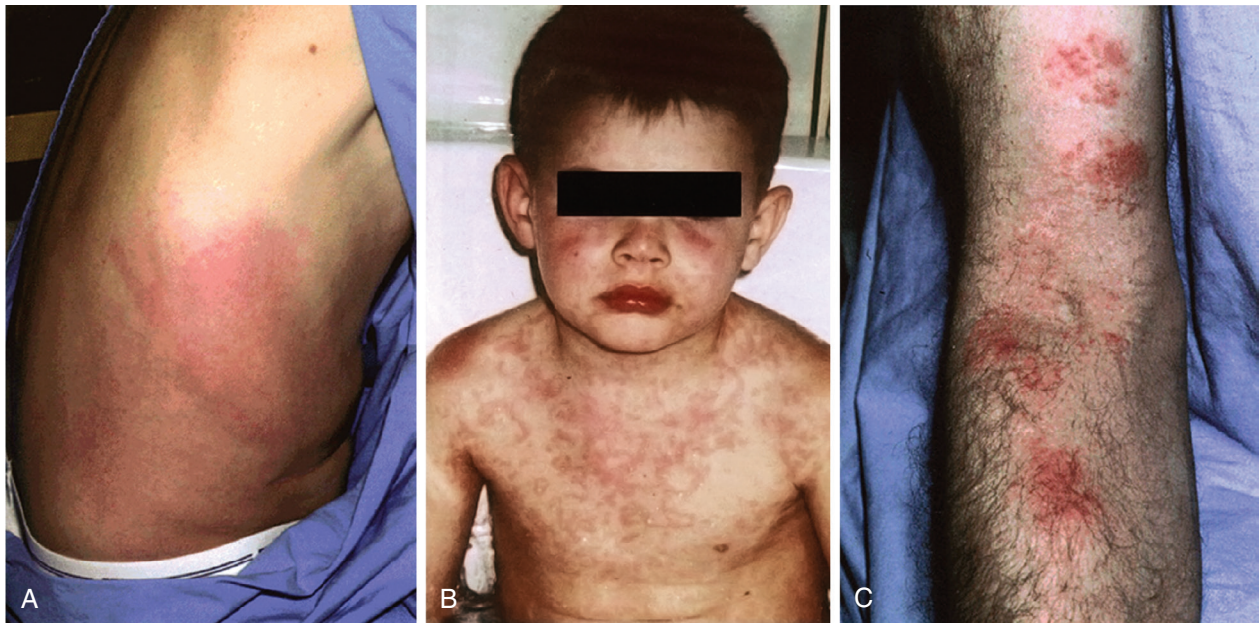

Fig. 188.6 Cutaneous manifestations of tumor necrosis factor receptor-associated periodic syndrome. **A**, Right flank of a patient with the T50M mutation. **B**, Serpiginous rash involving the face, neck, torso, and upper extremities of a child with the C30S mutation. **C**, Erythematous, macular patches with crusting on the flexor surface of the right arm of a patient with the T50M mutation. (From Hull KM, Drewe E, Aksentijevich I, et al: *The TNF receptor-associated periodic syndrome [TRAPS]: emerging concepts of an autoinflammatory syndrome*, *Medicine (Baltimore)* 81:349–368, 2002.)

Table 188.8 Diagnostic Indicators of Tumor Necrosis Factor Receptor–Associated Periodic Syndrome (TRAPS)

1. Recurrent episodes of inflammatory symptoms spanning >6 mo duration (several symptoms generally occur simultaneously)
 - a. Fever
 - b. Abdominal pain
 - c. Myalgia (migratory)
 - d. Rash (erythematous macular rash occurs with myalgia)
 - e. Conjunctivitis or periorbital edema
 - f. Chest pain
 - g. Arthralgia or monoarticular synovitis
2. Episodes last >5 days on average (although variable)
3. Responsive to glucocorticosteroids but not colchicine
4. Affects family members in autosomal dominant pattern (although may not always be present)
5. Any ethnicity may be affected

From Hull KM, Drewe E, Aksentijevich I, et al: *The TNF receptor-associated periodic syndrome (TRAPS): emerging concepts of an autoinflammatory disorder*, *Medicine (Baltimore)* 81:349–368, 2002.

substitution of another amino acid for a highly conserved cysteine residue, thus disrupting disulfide bonds and leading to protein misfolding. A number of other missense mutations not involving cysteine residues have been shown to have a similar effect on TNFR1 protein folding. Misfolded TNFR1 aggregates intracellularly and leads to constitutive signaling through mitogen-activated protein kinases or nuclear factor (NF)- κ B, resulting in the release of proinflammatory cytokines such as IL-6, IL-1 β and TNF- α . The substitution of glutamine for arginine at residue 92 (R92Q) and the substitution of leucine for proline at residue 46 (P46L) are seen in >1% of the white and black population, respectively. These variants do not lead to the same biochemical or signaling abnormalities seen with more-severe TRAPS mutations, and as with E148Q in FMF, debate surrounds whether they are mild mutations or functional polymorphisms.

Colchicine is generally not effective in TRAPS. For relatively mild disease, NSAIDs may suffice. For more severe disease with infrequent

attacks, corticosteroids at the time of an attack may be effective, but it is not unusual for steroid requirements to increase over time. Etanercept is often effective in reducing the severity and frequency of flares, but longitudinal follow-up of TRAPS patients treated with etanercept indicates waning efficacy with time. Of note, treatment of TRAPS with anti-TNF- α monoclonal antibodies has sometimes led to a paradoxical worsening of disease. Clinical responses to anakinra, *canakinumab*, a monoclonal anti-IL-1 β antibody, and *tocilizumab*, a monoclonal anti-IL6 antibody, has been favorable in TRAPS patients.

Cryopyrin-Associated Periodic Fever Syndromes

CAPS represent a spectrum of clinical disorders, including **familial cold autoinflammatory syndrome (FCAS)**, **Muckle-Wells syndrome (MWS)**, and **neonatal-onset multisystem inflammatory disorder (NOMID)**. Although 3 separate clinical diagnoses have been defined, it should be emphasized that the **cryopyrinopathies** are really a continuum of disease severity. This spectrum of illness is caused by mutations in *NLRP3* (formerly known as *CIAS1*), which encodes a protein called **cryopyrin**; >100 disease-associated *NLRP3* mutations have been enumerated on the *Infefers* online database. Advances in next-generation sequencing have also permitted the identification of symptomatic individuals with somatic *NLRP3* mosaicism.

NLRP3 is a PYRIN domain-containing protein that is strongly expressed in myeloid cells and to a lesser degree in other tissues. It is a part of a macromolecular complex termed the *NLRP3 inflammasome* that activates pro-IL-1 β to its mature form in response to a variety of endogenous danger-associated molecular patterns and pathogen-associated molecular patterns. Patients with cryopyrinopathies have *gain-of-function mutations* in *NLRP3* that result in constitutive or easily-triggered activation of the *NLRP3 inflammasome*.

The cryopyrinopathies are characterized by recurrent fevers and an urticaria-like rash that develops early in infancy (Fig. 188.7). Histopathologic examination reveals a perivascular neutrophilic infiltrate without the mast cells or mast cell degranulation seen with true urticaria. In patients with FCAS, febrile attacks generally begin 1–3 hr after generalized cold exposure. FCAS patients also experience polyarthralgia of the hands, knees, and ankles, and conjunctivitis may also develop during attacks. FCAS episodes are self-limited and generally resolve within

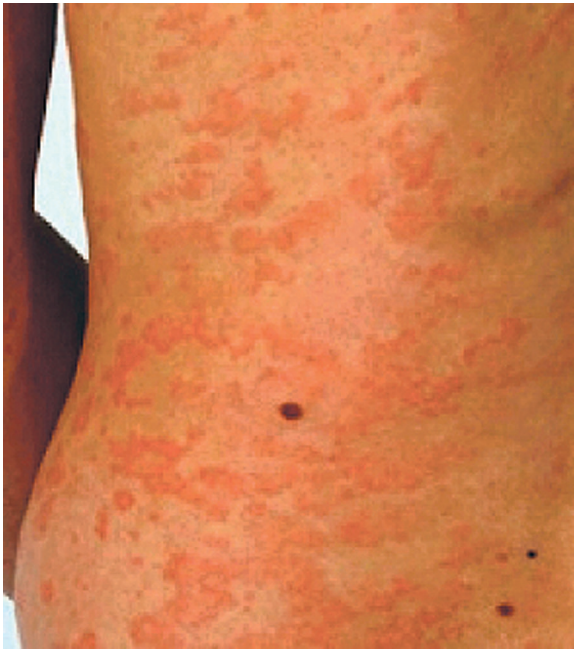

Fig. 188.7 Urticarial-like rash. Inflammatory clinical manifestations and organ damage in the IL-1-mediated diseases; in neonatal-onset multisystem inflammatory disease (NOMID), which is the severe form of cryopyrin-associated periodic syndromes (CAPS); and deficiency of IL-1 receptor antagonist (DIRA). This rash is not truly urticarial and occurs due to neutrophil infiltrates into the skin. (From Jesus AA, Goldbach-Mansky R: IL-1 blockade in autoinflammatory syndromes. *Annu Rev Med* 65:223–244, 2014, Fig. 2.)

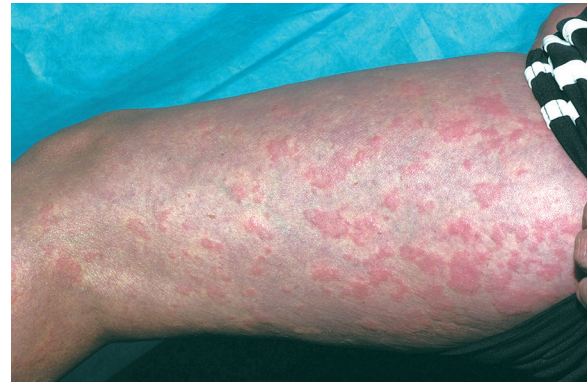


Fig. 188.8 Urticarial-like skin rash in a patient with Muckle-Wells syndrome. (Courtesy Dr. D. L. Kastner, National Institutes of Health, Bethesda, Maryland; from Simon A, van der Meer JWM, Drenth JPH: Familial autoinflammatory syndromes. In Firestein GS, Budd RC, Gabriel SE, et al, editors: *Kelley's textbook of rheumatology*, ed 9, Philadelphia, 2012, Saunders, Fig 97-14.)

Table 188.9 Diagnostic Criteria for Familial Cold Autoinflammatory Syndrome (FCAS)

1. Recurrent intermittent episodes of fever and rash that primarily follow generalized cold exposures
2. Autosomal dominant pattern of disease inheritance
3. Age of onset <6 mo
4. Duration of most attacks <24 hr
5. Presence of conjunctivitis associated with attacks
6. Absence of deafness, periorbital edema, lymphadenopathy, and serositis

From Hoffman HM, Wanderer AA, Broide DH: Familial cold autoinflammatory syndrome: phenotype and genotype of an autosomal dominant periodic fever, *J Allergy Clin Immunol* 108:615–620, 2001.

24 hr. AA amyloidosis rarely occurs in FCAS. Table 188.9 lists diagnostic criteria for FCAS.

In contrast to FCAS, the febrile episodes of MWS are not cold induced but are characterized by the same urticarial-like rash seen in FCAS (Fig. 188.8). Many MWS patients also develop progressive sensorineural hearing loss, and untreated, approximately 30% of MWS patients develop AA amyloidosis. NOMID patients present in the neonatal period with a diffuse, urticarial rash, daily fevers, and dysmorphic features (Fig. 188.9). Significant joint deformities, particularly of the knees, may develop because of bony overgrowth of the epiphyses of the long bones (Fig. 188.10). NOMID patients also develop chronic aseptic meningitis, leading to increased intracranial pressure, optic disc edema, visual impairment, progressive sensorineural hearing loss, and intellectual disability (Fig. 188.11).

Targeted therapy with anakinra (recombinant IL-1R antagonist) has been life changing for NOMID patients, not only controlling fever and rash, but also preventing end-organ damage. Anakinra, riloncept, and canakinumab are all effective in both FCAS and MWS; they are approved

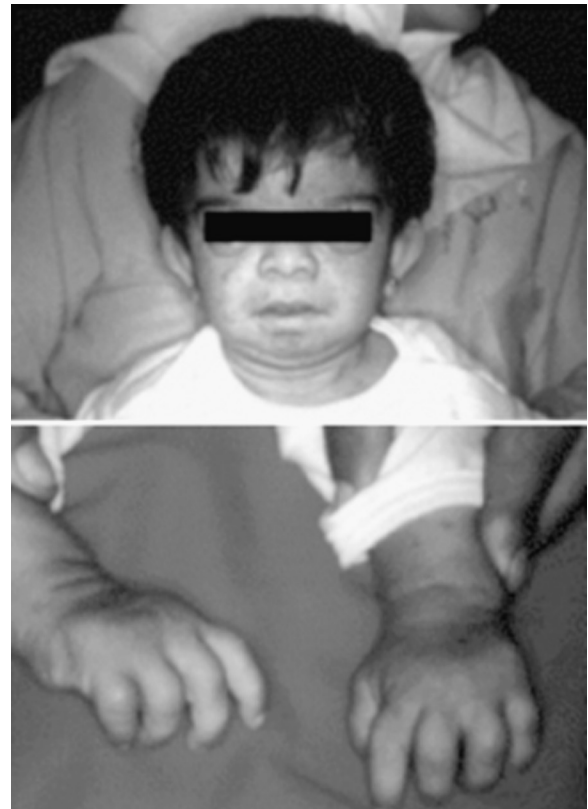

Fig. 188.9 A 3 yr old girl with NOMID/CINCA disease. Note the markedly deformed hands, rash, frontal bossing, and large head. (From Padeh S: Periodic fever syndromes, *Pediatr Clin North Am* 52:577–560, 2005.)

by the U.S. Food and Drug Administration (FDA) for both conditions. Aggressive IL-1 blockade has resulted in attenuation of amyloidosis in the cryopyrinopathies.

OTHER MENDELIAN AUTOINFLAMMATORY DISEASES

Syndrome of Pyogenic Arthritis With Pyoderma Gangrenosum and Acne

PAPA syndrome is a rare autosomal dominant disorder caused by mutations in *PSTPIP1*, a gene that encodes the cytoskeletal proline

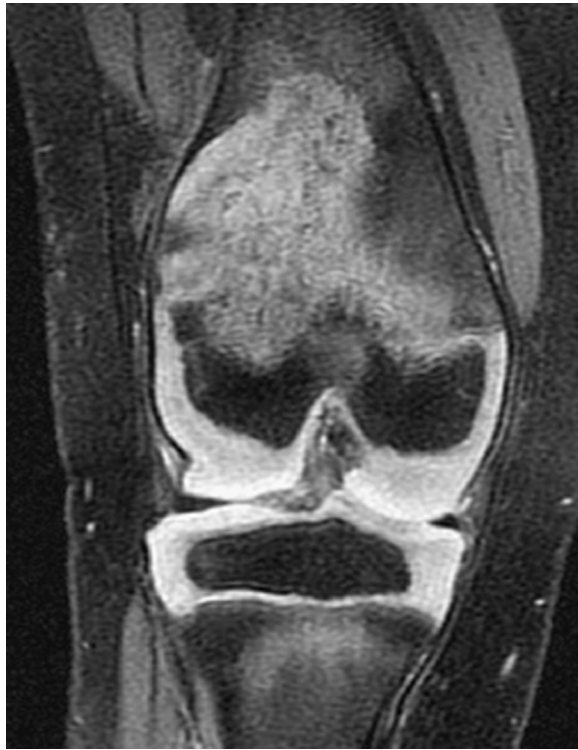


Fig. 188.10 Metaphyseal bone overgrowth. Inflammatory clinical manifestations and organ damage in the IL-1-mediated diseases; in NOMID, the severe form of CAPS; and DIRA. (From Jesus AA, Goldbach-Mansky R: *IL-1 blockade in autoinflammatory syndromes*. *Annu Rev Med* 65:223–244, 2014, Fig 2.)

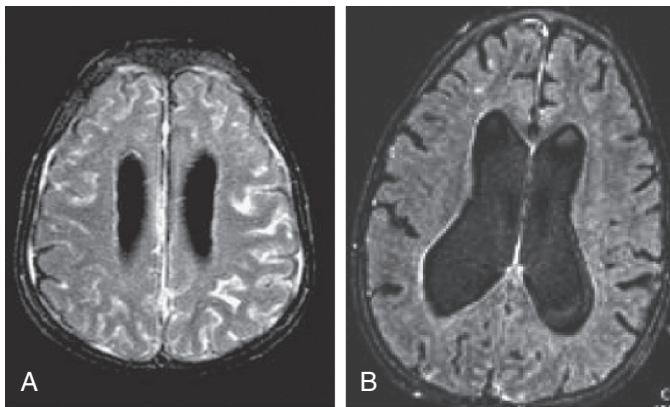


Fig. 188.11 **A**, Leptomeningeal enhancement; **B**, hydrocephalus and cerebral atrophy. Inflammatory clinical manifestations and organ damage in the IL-1-mediated diseases, NOMID (severe form of CAPS), and DIRA. (From Jesus AA, Goldbach-Mansky R: *IL-1 blockade in autoinflammatory syndromes*, *Annu Rev Med* 65:223–244, 2014, Fig 2.)

serine threonine phosphatase-interacting protein-1 (PSTPIP). The PSTPIP1 protein interacts with a number of immunologically important molecules, including CD2, the Wiskott-Aldrich syndrome protein (WASP), and pyrin. PAPA-associated *PSTPIP1* mutations greatly increase its affinity to pyrin and cause increased IL-1 β production.

Clinical manifestations of PAPA syndrome begin in early childhood with recurrent episodes of sterile, pyogenic arthritis that leads to erosions and joint destruction, and appears to develop spontaneously or after minor trauma. Fever is not a dominant feature. Cutaneous manifestations tend to develop in adolescence, at which time patients are prone to developing severe cystic acne. Additionally, PAPA patients commonly

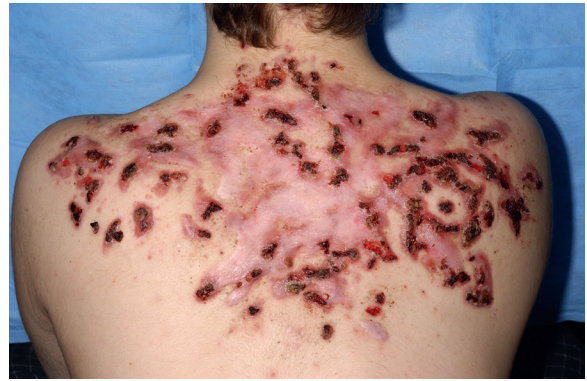

Fig. 188.12 Pyoderma gangrenosum lesions in a patient with PAPA syndrome and the A230T mutation in *PSTPIP1*. Note the diffuse scarring indicative of prior lesions on his upper back.

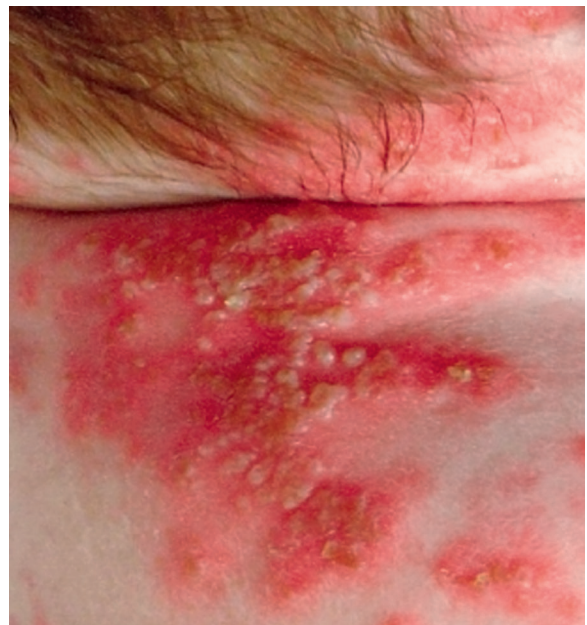

Fig. 188.13 Pustular rash. Inflammatory clinical manifestations and organ damage in the IL-1-mediated diseases, NOMID (severe form of CAPS), and DIRA. This can also be seen in deficiency of IL-36 receptor antagonist (DITRA). (From Jesus AA, Goldbach-Mansky R: *IL-1 blockade in autoinflammatory syndromes*, *Annu Rev Med* 65:223–244, 2014, Fig 2.)

develop ulcerating pyoderma gangrenosum lesions (Fig. 188.12), and some develop pathergy reactions.

The treatment of PAPA syndrome may involve the use of corticosteroids, IL-1 antagonists, and TNF- α inhibitors, sometimes in combination. The joint manifestations of PAPA appear to respond to IL-1 blockade, whereas the cutaneous manifestations seem to respond more favorably to TNF- α blockade. Local measures, such as joint aspiration and drainage and intensive wound care, are also important in the care of PAPA patients, as is pain management for cutaneous disease. Caution should be taken when prescribing sulfonamides because some PAPA patients develop pancytopenia.

Deficiency of Interleukin-1 Receptor Antagonist

DIRA is an autosomal recessive autoinflammatory disease that is distinct from the cryopyrinopathies. DIRA typically presents in the neonatal period with systemic inflammation and a neutrophilic pustulosis, sterile multifocal osteomyelitis, widening of the anterior ends of the ribs, periostitis, and osteopenia (Figs. 188.13 and 188.14). Although fever is

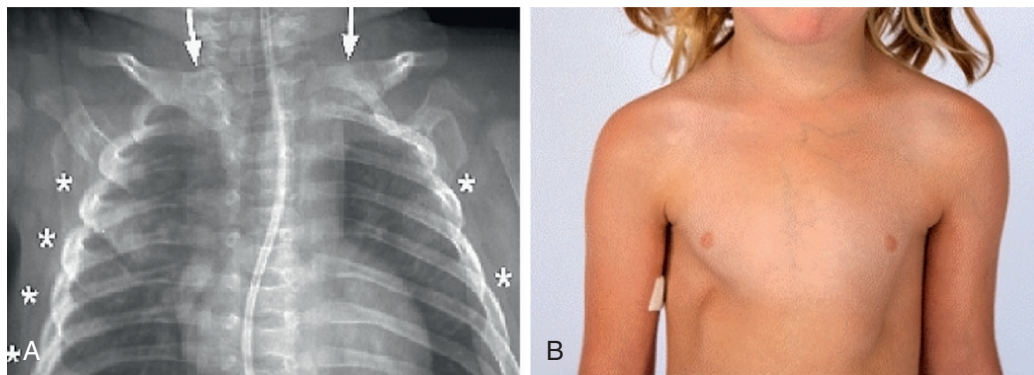


Fig. 188.14 **A**, Widening of multiple ribs (*) and clavicles (arrows) in DIRA osteomyelitis; **B**, chest deformity. Inflammatory clinical manifestations and organ damage in the IL-1-mediated diseases, NOMID, and DIRA. (From Jesus AA, Goldbach-Mansky R: IL-1 blockade in autoinflammatory syndromes, *Annu Rev Med* 65:223–244, 2014, Fig 2.)

not a prominent clinical feature, patients do have greatly elevated acute-phase reactants. Multiorgan failure and pulmonary interstitial fibrosis can occur and can be fatal.

DIRA is caused by loss-of-function mutations in *IL1RN*, encoding the IL-1R antagonist. Because of the lack of antagonistic activity, the cells are hyperresponsive to IL-1 β stimulation. Numerous treatments for DIRA have been tried, including NSAIDs, glucocorticoids, intravenous immune globulin (IVIG), methotrexate, cyclosporine, and etanercept. However, *anakinra is the treatment of choice*, essentially replacing the lost protein and resulting in a rapid clinical response. Anakinra is dosed daily, with the dose titrated to achieve a normal CRP. There are now longer-acting anti-IL-1 agents, canakinumab and rilonacept, which are effective and require less frequent dosing than anakinra.

Blau Syndrome

Blau syndrome is a rare autosomal dominant disorder that manifests as early-onset (<5 yr of age) granulomatous arthritis, uveitis, and rash. The arthritis may affect the ankles and wrists and may lead to flexion contractures of the fingers and toes (camptodactyly). **Early-onset sarcoidosis** presents with a similar clinical picture, sometimes with visceral involvement, and both conditions are caused by mutations in the caspase recruitment domain protein 15 (*CARD15*), also known as nucleotide-binding oligomerization domain-2 protein (*NOD2*). *NOD2* is an intracellular sensor of bacterial products in DCs, myelomonocytic cells, and Paneth cells. Mutations in the NACHT oligomerization domain of this protein cause Blau syndrome/early-onset sarcoidosis, whereas variants primarily in the leucine-rich repeat domain are associated with susceptibility to **Crohn disease**. Corticosteroids have been the mainstay of therapy for Blau syndrome. There are a number of case reports of the beneficial effects of TNF- α inhibitors in Blau syndrome.

Autoinflammation With Phospholipase C γ_2 -Associated Antibody Deficiency and Immune Dysregulation

APLAID is a dominantly inherited disorder characterized by recurrent blistering skin lesions, bronchiolitis, arthralgia, ocular inflammation, enterocolitis, absence of autoantibodies, and mild immunodeficiency. Rash is the first manifestation of APLAID, which is described as a full-body epidermolysis bullosa-like eruption. Over time, this rash changes to recurrent plaques and vesiculopustular lesions that are triggered by heat and sunlight. Colitis also presents in childhood before age 5 yr. Ocular manifestations begin before age 1 yr and include corneal ulcerations and erosions as well as cataracts. Immune manifestations include markedly decreased class-switched memory B cells, resulting in low IgM and IgA.

Patients with APLAID show a gain-of-function missense mutation in the autoinhibitory region of phospholipase C γ_2 (PLC γ_2), leading to increased activity of downstream mediators and stimulation of lymphocytes. Despite the enhanced signaling, the resulting populations of

immune cells have poor function. Interestingly, a different mutation in the PLC γ_2 complex leads to a syndrome known as **PLC γ_2 -associated antibody deficiency and immune dysregulation (PLAID)**, characterized by cold-induced urticaria, hypogammaglobulinemia with resulting susceptibility to infection, and autoimmunity.

Because of the low number of affected patients described, there are no agreed treatment regimens for APLAID. Patients have been treated with NSAIDs, and corticosteroids can be effective, but side effects limit their long term use. TNF- α inhibitors and IL-1 inhibitors have been used with some success.

Deficiency of Adenosine Deaminase 2

DADA2 is an autoinflammatory disorder caused by loss-of-function mutations in *CECR1*, encoding adenosine deaminase 2. DADA2 presents with recurrent fevers and a spectrum of vascular manifestations that includes livedo racemosa, early-onset ischemic lacunar strokes, and systemic vasculitis of medium size vessels similar to **polyarteritis nodosa**. The lacunar strokes, typically affecting the deep brain nuclei and the brainstem, transpire before age 5 yr and typically occur during inflammatory episodes. The livedoid rash is also a prominent feature during inflammatory episodes, and biopsies demonstrate a predominance of neutrophils and macrophages as well as vasculitis in medium-sized vessels. Acute-phase reactants are typically elevated. Other features include ophthalmologic involvement, various degrees of lymphopenia, hypogammaglobulinemia (usually IgM), hepatosplenomegaly, portal hypertension, and neutropenia. Patients may meet criteria for polyarteritis nodosa and can exhibit digit necrosis and Raynaud phenomenon.

ADA2 is produced primarily by monocytes and macrophages, is found in plasma, and appears to act as a growth and differentiation factor for a subset of inflammatory macrophages. Numerous antiinflammatories have been tried in patients with DADA2, including glucocorticoids and cyclophosphamide. TNF- α inhibitors (etanercept or adalimumab) are the mainstay of treatment, and anecdotal reports have shown a benefit of anakinra. Macrophages and monocytes are the main sources of ADA2, raising the possibility of bone marrow transplant to achieve a permanent cure.

Sideroblastic Anemia With Immunodeficiency, Fevers, and Development Delay

SIFD is a syndrome characterized by systemic inflammation, fevers, enteritis, and sideroblastic anemia and caused by biallelic mutations in *TRNT1*. SIFD presents in infancy with fever, elevated inflammatory markers, gastroenteritis, and anemia. Bone marrow biopsies demonstrate ringed sideroblasts. Other features include hypogammaglobulinemia, B-cell lymphopenia, developmental delay, and variable neurodevelopmental degeneration, seizures, and sensorineural hearing loss. Brain imaging was notable for cerebellar atrophy, delayed white matter myelination, and decreased perfusion. Other, isolated clinical features include nephrocalcinosis, aminoaciduria, ichthyotic skin, cardiomyopathy,

and retinitis pigmentosa. TRNT1 is an RNA polymerase that is necessary for maturation of cytosolic and mitochondrial transfer RNAs, by the addition of 2 cytosines and 1 adenosine to the tRNA ends.

Symptomatic treatment with regular blood transfusions and immunoglobulin replacement therapy is the mainstay of SIFD therapy. Iron overload from the transfusion often requires chelation therapy. Anakinra relieved the febrile episodes in one patient but did not alter the other clinical manifestations. Patients with SIFD have a high mortality rate. One patient underwent hematopoietic bone marrow transplantation at 9 mo of age that resulted in correction of the hematologic and immunologic abnormalities.

Deficiency of Interleukin-36 Receptor Antagonist (DITRA)

DITRA is characterized by episodes of diffuse erythematous pustular rash (generalized pustular psoriasis), fevers, general malaise, and systemic inflammation. Attacks can be triggered by events such as infections, pregnancy, or menstruation or can occur randomly. The underlying genetic etiology has been determined to be autosomal recessive mutations in the *IL36RN* gene, which encodes an IL-36R antagonist. IL-36 is related to and acts similarly to IL1R antagonist, preventing production of inflammatory cytokines such as IL-8. Interestingly, the rash of DITRA is similar to the rash of DIRA (IL-1R deficiency; see earlier), but DITRA is largely skin limited. DITRA has been treated with various modalities, including vitamin A analogs, cyclosporine, methotrexate, and TNF- α inhibitors. The use of anakinra has been described in case reports and results in alleviation of the symptoms.

Familial Cold Autoinflammatory Syndrome Type 2

Mutations in *NLRP12* lead to a periodic fever syndrome characterized by fevers $>40^{\circ}\text{C}$, arthralgias, and myalgias lasting from 2–10 days. This disorder is named FCAS2 because these episodes can be precipitated by cold. Clinical findings may include an urticarial-like rash, abdominal pain and vomiting, aphthous ulcers, and lymphadenopathy. As with Muckle-Wells syndrome, sensorineural hearing loss and optic neuritis have been described. NALP12 is a member of the CATERPILLAR family of proteins, which are important in innate immunity. Similar to Toll-like receptors (TLRs) that act to recognize pathogen-associated molecular patterns (PAMPs), NLRP12 also senses PAMPs and can lead to the activation of the inflammasome and generation of IL-1 β . Treatment of *NALP12* mutations was difficult until the advent of anti-IL-1 agents (e.g., anakinra), which are the preferred treatment for FCAS2 and result in remarkable resolution of symptoms. Colchicine can be partially effective, and systemic glucocorticoids can reduce the duration of the attacks.

Autoinflammation With Enterocolitis

A disorder caused by mutations in *NLR4* was described with neonatal-onset enterocolitis, fever, and autoinflammatory episodes. Inflammatory markers are typically elevated, including CRP and ferritin. **Macrophage activation syndrome**, characterized by pancytopenia, hypertriglyceridemia, and coagulopathies, is common during acute flares, which can be precipitated by emotional and physical stress. Recurrent myalgias with febrile episodes often occur as well. This disorder is caused by gain-of-function missense mutations in NOD-like receptor C4 (*NLR4*), which normally aids in the activation of the inflammasome. The resulting protein leads to constitutive production of IL-1. The mainstay of treatment is anti-IL-1 agents such as anakinra, canakinumab, and rilonacept. Before their diagnosis, patients with *NLR4* mutations had been treated with colchicine and oral glucocorticoids, with varying success.

Majeed Syndrome

Majeed syndrome is an autosomal recessive disorder caused by mutations in the *LPIN2* gene (see Table 188.4). The clinical manifestation of Majeed syndrome begin in childhood with recurrent fevers, sterile osteomyelitis, congenital dyserythropoietic anemia (CDA), neutrophilic dermatosis, failure to thrive, and hepatomegaly. Treatment of Majeed syndrome has included NSAIDs, corticosteroids, and IL-1R antagonist. How mutations in *LPIN2* lead to an autoinflammatory disorder is not known.

Interferonopathies

Type 1 interferons (IFN- α and IFN- β) are the first line of defense against viral infections and are produced by a variety of cell types. During viral infections, a variety of products are made by the virus, including ssRNA, dsRNA, and CpG-containing DNA, and are recognized by intracellular sensors. These sensors then induce type 1 IFN production that activates IFN receptors and activates IFN-responsive genes to help control the spread of the virus until the adaptive immune system can be activated to clear the virus. Inappropriate activation of these pathways leads to IFN production and interferonopathies.

Chronic Atypical Neutrophilic Dermatitis With Lipodystrophy and Elevated Temperature

CANDLE syndrome, also known as **proteasome-associated autoinflammatory syndrome (PRAAS) or joint contractures, muscular atrophy, panniculitis-induced lipodystrophy (JMP) syndrome**, is an autosomal recessive disease. Patients present early in life with recurrent fevers and systemic inflammation; skin involvement, including annular erythema, erythema nodosum-like panniculitis, or neutrophilic dermatosis; small joint contractures; lipodystrophy; muscle atrophy or myositis; violaceous eyelid swelling; and anemia. Conjunctivitis, aseptic meningitis, and organomegaly are common. Acute-phase reactants and platelet counts are elevated. Autoimmunity can occur, including Coombs-positive hemolytic anemia and hypothyroidism. Intelligence and development are typically spared, although mild developmental delays have been reported. CANDLE is caused by loss-of-function mutations in *PSMB8*, the gene that encodes the $\beta 5i$ subunit of the proteasome. Proteasomes are important in the degradation of ubiquitinated proteins to ensure proper protein homeostasis, and defects in proteasomes result in cellular stress and inflammatory cytokine release, including type 1 interferons.

There is no established treatment for CANDLE, although multiple treatment modalities have been attempted, including colchicine, dapsone, cyclosporine, infliximab, and etanercept, all with minimal success. Glucocorticoids and methotrexate have provided slight improvement in symptoms. Anakinra has not proved successful, whereas IL-6–blocking agents have shown some benefit. Since interferon receptors use the JAK/STAT pathway to signal, JAK inhibitors (tofacitinib, ruxolitinib, and baricitinib) show promise.

STING-Associated Vasculopathy With Onset in Infancy

SAVI is a rare disorder that presents in infancy. It is caused by mutations in the *TMEM173* gene, which encodes for the stimulator of interferon genes (STING). Systemic inflammation is an early manifestation, with fever and elevated inflammatory markers. Skin involvement includes a neutrophilic rash as well as violaceous lesions of fingers, toes, nose, cheeks, and ears. These lesions worsen over time and can become necrotic with vascular occlusion. Histology of the lesions reveals dermal inflammation with leukocytoclastic vasculitis and microthrombotic angiopathy. Since STING is also expressed in pulmonary epithelium, SAVI patients also developed pulmonary complications, including paratracheal adenopathy, interstitial lung disease, and fibrosis.

STING is an adapter protein of the intracellular DNA sensing machinery and mediates the production of interferon- β (IFN- β). The IFN- β then signals through the IFN receptor by activating the JAK/STAT signaling pathway and downstream IFN-responsive genes, including IL-6 and TNF- α . Mutations in STING that cause SAVI are de novo gain-of-function mutations that activate spontaneous IFN- β production.

Treatment options for patients with SAVI are limited at this time, although recent data with JAK inhibitors (tofacitinib, ruxolitinib, and baricitinib) have shown promise in blocking IFN- β receptor signaling and the activation of IFN-response genes.

GENETICALLY COMPLEX AUTOINFLAMMATORY DISEASES Periodic Fever, Aphthous Stomatitis, Pharyngitis, and Adenitis

PFAPA is the most common recurrent fever syndrome in children. It usually presents between ages 2 and 5 yr with recurring episodes of

fever, malaise, exudative-appearing tonsillitis with negative throat cultures, cervical lymphadenopathy, oral aphthae, and less often headache, abdominal pain, and arthralgia. The episodes last 4-6 days, regardless of antipyretic or antibiotic treatment, and often occur with clock-like regularity on 3-6 wk cycles. Findings during the episodes may include mild hepatosplenomegaly, mild leukocytosis, and elevated acute-phase reactants. Both the frequency and the intensity of the episodes diminish with increasing age. The etiology and pathogenesis of PFAPA remain unknown.

Most patients show dramatic response to a single oral dose of prednisone (0.6-2.0 mg/kg), although this approach does not prevent recurrence and may actually shorten the interval between flares. Cimetidine at 20-40 mg/kg/day is effective at preventing recurrences in approximately one third of cases. Small series have shown that anakinra may be effective during a flare, but because corticosteroids are effective, this may not be a cost-effective approach. Colchicine may extend the time between flares. Complete resolution has been reported after tonsillectomy, although medical management should be the first approach.

Chronic Recurrent Multifocal Osteomyelitis

CRMO is a form of inflammatory bone disease most frequently seen in children (see Table 188.4). Histologically and radiologically, CRMO is virtually indistinguishable from infectious osteomyelitis (Fig. 188.15). Patients typically present with bone pain and may also have fever, soft tissue swelling, and elevated acute-phase reactants. Cultures are sterile. Typically involved bones include the distal femur, proximal tibia or fibula, spine, and pelvis. Both metaphyseal and epiphyseal lesions may occur; premature physeal closure may develop. Less frequently involved bones include the clavicle and mandible. The differential diagnosis includes infectious osteomyelitis, histiocytosis, and malignancy (neuroblastoma, lymphoma, leukemia, Ewing sarcoma). **SAPHO** (synovitis, acne, pustulosis, hyperostosis, and osteitis) may be an adult equivalent to CRMO.

The etiology of sporadic CRMO is unknown. CRMO is seen in Majeeed syndrome (see earlier), in association with inflammatory bowel disease, and inflammatory skin disease such as palmoplantar pustulosis. Initial therapy includes NSAIDs. Second-line treatments include corticosteroids, TNF inhibitors, and bisphosphonates.

Bibliography is available at Expert Consult.

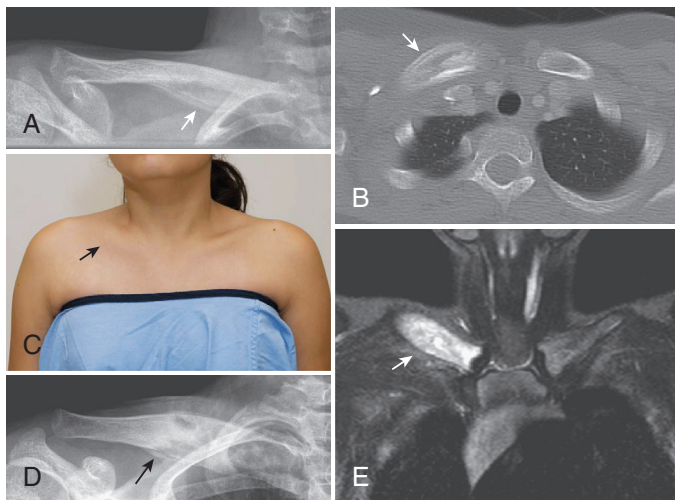


Fig. 188.15 Clavicular involvement in chronic recurrent multifocal osteomyelitis. Adolescent female with unilateral clavicular involvement. **A**, Plain radiograph of the right clavicle at presentation reveals widening of the medial two thirds, with associated periosteal reaction. **B**, Corresponding CT scan of the right clavicle demonstrates expansion of the medial right clavicle with areas of increased sclerosis accompanied by a surrounding periosteal reaction (arrow). **C**, Flare of disease 18 months later showing further clavicular enlargement (clinical photo). **D**, Plain radiograph of the right clavicle at that time demonstrates marked interval sclerosis and thickening. **E**, MRI at the same time shows increased signal intensity on fat-suppressed contrast-enhanced T1-weighted images of the right medial clavicle consistent with continued inflammation. (Images courtesy Dr. Paul Babyn, University of Saskatchewan and Saskatchewan Health Authority, Saskatchewan, Canada.)

Bibliography

- Akar S, Yuksel F, Tunca M, et al: Familial Mediterranean fever: risk factors, causes of death, and prognosis in the colchicine era, *Medicine (Baltimore)* 91:131–136, 2012.
- Aksentijevich I, Masters SL, Ferguson PJ, et al: An autoinflammatory disease with deficiency of the interleukin-1-receptor antagonist, *N Engl J Med* 360:2426–2437, 2009.
- Bader-Meunier B, Florkin B, Sibilia J, et al: SOFREMIP (Société Francophone pour la Rhumatologie et les Maladies Inflammatoires en Pédiatrie); CRI (Club Rhumatismes et Inflammations): mevalonate kinase deficiency: a survey of 50 patients, *Pediatrics* 128:e152–e159, 2011.
- Ben-Ami T, Revel-Vilk S, Brooks R, et al: Extending the clinical phenotype of adenosine deaminase 2 deficiency, *J Pediatr* 177:316–320, 2016.
- Boisson B, Laplantine E, Dobbs K, et al: Human HOIP and LUBAC deficiency underlies autoinflammation, immunodeficiency, amylopectinosis, and lymphangiectasia, *J Exp Med* 212(6):939–951, 2015.
- Bulua AC, Mogul DB, Aksentijevich I, et al: Efficacy of etanercept in the tumor necrosis factor receptor–associated periodic syndrome: a prospective, open-label, dose-escalation study, *Arthritis Rheum* 64:908–913, 2012.
- Canna SW, de Jesus AA, Gouni S, et al: An activating NLR4 inflammasome mutation causes autoinflammation with recurrent macrophage activation syndrome, *Nat Genet* 46(10):1140–1146, 2014.
- Carneiro S, Sampaio-Barros PD: SAPHO syndrome, *Rheum Dis Clin North Am* 39:401–418, 2013.
- Chae JJ, Cho Y-H, Lee G-S, et al: Gain-of-function mutations induce NLRP3 protein-independent interleukin-1 β activation and severe autoinflammation in mice, *Immunity* 34:755–768, 2011.
- Chakraborty PK, Schmitz-Abe K, Kennedy EK, et al: Mutation in *TRNT1* cause congenital sideroblastic anemia with immunodeficiency, fevers, and developmental delay (SIFD), *Blood* 124:2867–2871, 2014.
- Crow YJ, Casanova JL: STING-associated vasculopathy with onset in infancy—a new interferonopathy, *N Engl J Med* 371:568–572, 2014.
- Dagan E, Gershoni-Baruch R, Khatib I, et al: MEFV, TNF1 α , CARD15 and NLRP3 mutation analysis in PFAPA, *Rheumatol Int* 30:633–636, 2010.
- Elkan PN, Pierce SB, Segel R, et al: Mutant adenosine deaminase 2 in a polyarteritis nodosa vasculopathy, *N Engl J Med* 370:917–927, 2014.
- Fritz J, Tzairbatchev N, Claussen CD, et al: Chronic recurrent multifocal osteomyelitis: comparison of whole-body MR imaging with radiography and correlation with clinical and laboratory data, *Radiology* 252(3):842–851, 2009.
- Garavello W, Pignataro L, Gaini L, et al: Tonsillectomy in children with periodic fever with aphthous stomatitis, pharyngitis, and adenitis syndrome, *J Pediatr* 159:138–142, 2011.
- Gattorno M, Obici L, Cattalini M, et al: Canakinumab treatment for patients with active recurrent or chronic TNF receptor–associated periodic syndrome (TRAPS): an open-label, phase II study, *Ann Rheum Dis* 76(1):173–178, 2017.
- Hashkes PJ, Toker O: Autoinflammatory syndromes, *Pediatr Clin North Am* 59:447–470, 2012.
- Herlin T, Fiirgaard B, Bjerre M, et al: Efficacy of anti-IL-1 treatment in Majeeed syndrome, *Ann Rheum Dis* 72:410–413, 2013.
- Jesus AA, Goldbach-Mansky R: IL-1 blockade in autoinflammatory syndromes, *Annu Rev Med* 65:223–244, 2014.
- La Regina M, Orlandini F, Manna R: Autoinflammatory diseases: a possible cause of thrombosis? *Thromb J* 13:19, 2015.
- Lachmann HJ, Papa R, Gerhold K, et al: Paediatric Rheumatology International Trials Organisation (PRINTO), the EUROTRAPS, and the Eurofever Project. The phenotype of TNF receptor–associated autoinflammatory syndrome (TRAPS) at presentation: a series of 158 cases from the Eurofever/EUROTRAPS international registry, *Ann Rheum Dis* 73(12):2160–2167, 2014.
- Lantto U, Koivunen P, Tapiainen T, Renko M: Long-term outcome of classic and incomplete PFAPA (periodic fever, aphthous stomatitis, pharyngitis, and adenitis) syndrome after tonsillectomy, *J Pediatr* 179:172–177, 2016.
- Levy M, Arion A, Berrebi D, et al: Severe early-onset colitis revealing mevalonate kinase deficiency, *Pediatrics* 132:e779–e783, 2013.
- Liu Y, Jesus B, Marrero D, et al: Activated STING in a vascular and pulmonary syndrome, *N Engl J Med* 371:507–518, 2014.
- Liu Y, Ramot Y, Torrello A, et al: Mutations in proteasome subunit β type 8 cause chronic atypical neutrophilic dermatosis with lipodystrophy and elevated temperature with evidence of genetic and phenotypic heterogeneity, *Arthritis Rheum* 64:895–907, 2012.
- Manukyan G, Aminov R: Update on pyrin functions and mechanisms of familial Mediterranean fever, *Front Microbiol* 7:456, 2016.
- Marrakchi S, Guigue P, Renshaw BR, et al: Interleukin-36-receptor antagonist deficiency and generalized pustular psoriasis, *N Engl J Med* 365(7):620–628, 2011.
- Martin-Nalda A, Roca I, Fontecha CG, et al: Chronic recurrent multifocal osteomyelitis and thalidomide in chronic granulomatous disease, *Pediatrics* 138(2):e20154017, 2016.
- Padeh S, Gerstein M, Berkun Y: Colchicine is a safe drug in children with familial Mediterranean fever, *J Pediatr* 161:1142–1146, 2012.
- Sanchez GA, de Jesus A, Goldbach-Mansky R: Monogenic autoinflammatory diseases: disorders of amplified danger sensing and cytokine dysregulation, *Rheum Dis Clin North Am* 39:701–734, 2013.
- Sibley CH, Plass N, Snow J, et al: Sustained response and prevention of damage progression in patients with neonatal-onset multisystem inflammatory disease treated with anakinra, *Arthritis Rheum* 64:2375–2386, 2012.
- Smith EJ, Allantaz F, Bennett L, et al: Clinical, molecular, and genetic characteristics of PAPA syndrome: a review, *Curr Genomics* 11:519–527, 2010.
- Stern SM, Ferguson PJ: Autoinflammatory bone diseases, *Rheum Dis Clin North Am* 39:735–749, 2013.
- Stojanov S, Lapidus S, Chitkara P, et al: Periodic fever, aphthous stomatitis, pharyngitis, and adenitis (PFAPA) is a disorder of innate immunity and Th1 activation responsive to IL-1 blockade, *Proc Natl Acad Sci USA* 108(7148):7153, 2011.
- Sfriso P, Caso F, Tognon S, et al: Blau syndrome, clinical and genetic aspects, *Autoimmun Rev* 12(1):44–51, 2012.
- Ter Haar NM, Jeyaratnam J, Lachmann HJ, et al: Paediatric Rheumatology International Trials Organisation and Eurofever Project. The phenotype and genotype of mevalonate kinase deficiency: a series of 114 cases from the Eurofever Registry, *Arthritis Rheumatol* 68(11):2795–2805, 2016.
- Verbsky JW: Monogenic causes of inflammatory disease in rheumatology, *Curr Opin Rheumatol* 24:506–514, 2012.
- Vigo G, Zulian F: Periodic fevers with aphthous stomatitis, pharyngitis, and adenitis (PFAPA), *Autoimmun Rev* 12:52–55, 2012.
- Wurster VM, Carlucci JG, Feder HM Jr, et al: Long-term follow-up of children with periodic fever, aphthous stomatitis, pharyngitis, and cervical adenitis syndrome, *J Pediatr* 159:958–964, 2011.
- Zerwas S, Larsen JT, Petersen L, et al: Eating disorders, autoimmune, and autoinflammatory disease, *Pediatrics* 140(6):e2016089, 2017.
- Zhou Q, Lee G-S, Brady J, et al: A hypermorphic missense mutation in *PLCG2*, encoding phospholipase C_{γ} , causes a dominantly inherited autoinflammatory disease with immunodeficiency, *Am J Hum Genet* 91:713–720, 2012.
- Zhou Q, Yang D, Ombrello AK, et al: Early-onset stroke and vasculopathy associated with mutations in *ADA2*, *N Engl J Med* 370:911–920, 2014.